

Head & Neck Surgeon's Infectiology

PD Dr. med. Andreas Arnold

Consultant

Department of ENT

Head & Neck Surgery

Inselspital

University of Bern

Head & Neck Surgeon's Infectiology


1. Introduction – when to grab the scalpel?
2. Anatomy
3. Surgical treatment

Head & Neck Surgeon's Infectiology

1. Introduction – when to grab the scalpel?
2. Anatomy
3. Surgical treatment



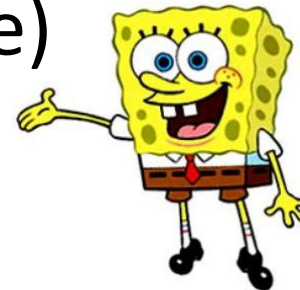
Owls to Athens



Abscess: purulent infection in a virtual space between tissues

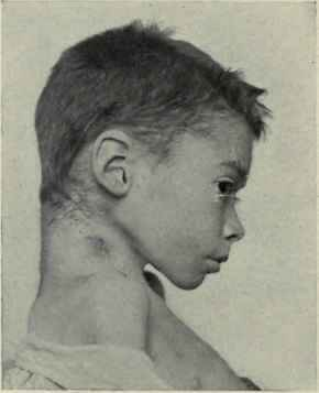Empyema: purulent infection in a pre-formed body cavity

Phlegmon: purulent infection with diffuse spread in the tissue (sponge-like)

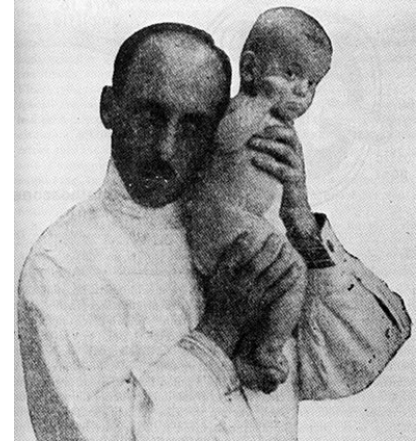

Cervical Phlegmon – Abscess

- **Origin:** „banal“ infection, post-traumatic, iatrogenic
- **Symptoms:** pain, trismus (=lockjaw), torticollis, aglutition, dyspnoea (= acute emergency)
- **Complication:** septic shock, asphyxia, vascular involvement with septic thrombosis or vascular invasion with lethal haemorrhage, tongue or vocal cord paresis, descending abscess => purulent mediastinitis, pericarditis and/or pleuritis




Ubi pus ibi evacua



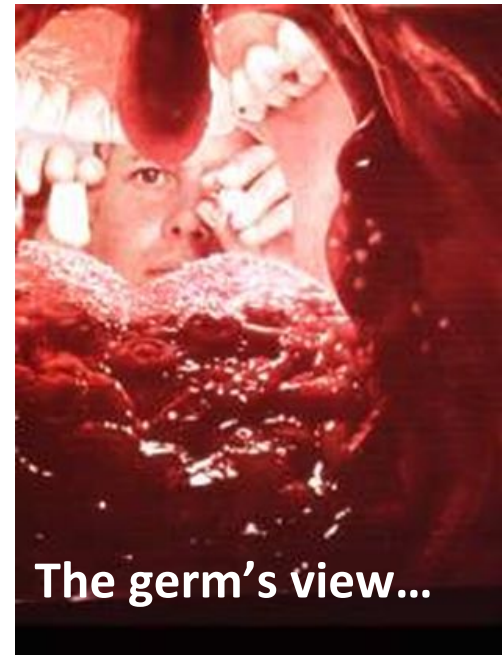
- Historically, decision making was easy for a surgeon:
 - No tomographic imaging => diagnostic surgery
 - No antibiotics => „septic surgery“ = evacuation as the only „causal“ therapy option: clean out the pus and rinse with antiseptic solutions
 - "Pus bonum et laudabile": in pre-20th century medicine the creamy-yellowish pus was regarded to be important in the wound healing process... (praise what you cannot fight...)

Today: Information Age

- Blood test: Haemogram, CRP
- Tomographic imaging : US, CT, MR +/- i.v. contrast agent
- Microbiology test from aspirate



- **Specific antibiotic therapy**
- So when to grasp the scalpel?



The germ's view...

When to grasp the scalpel?

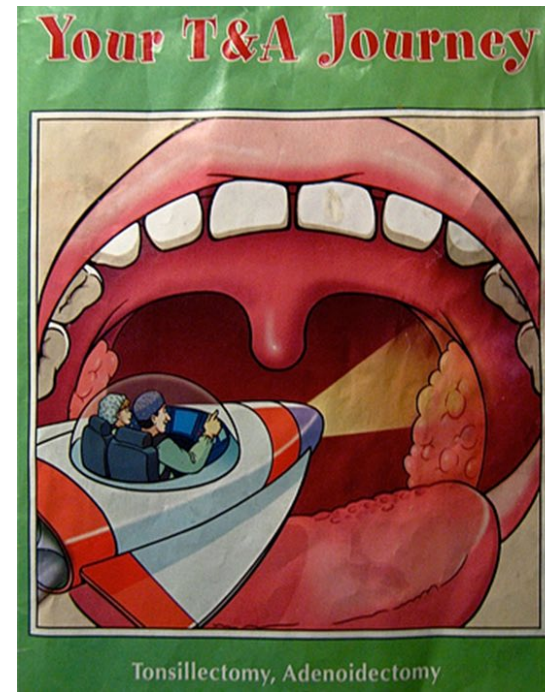
- Phlegmon/Mini-abscess: i.v. antibiotic therapy
- Antibiotics have merely no therapeutic effect in case of an abscess (pus encapsulated in a wall of granulation tissue). The antibiotic does not reach the area of purulent colliquation.
- Therefore: An abscess warrants surgical drainage of pus combined with antibiotics to avoid septic complications.

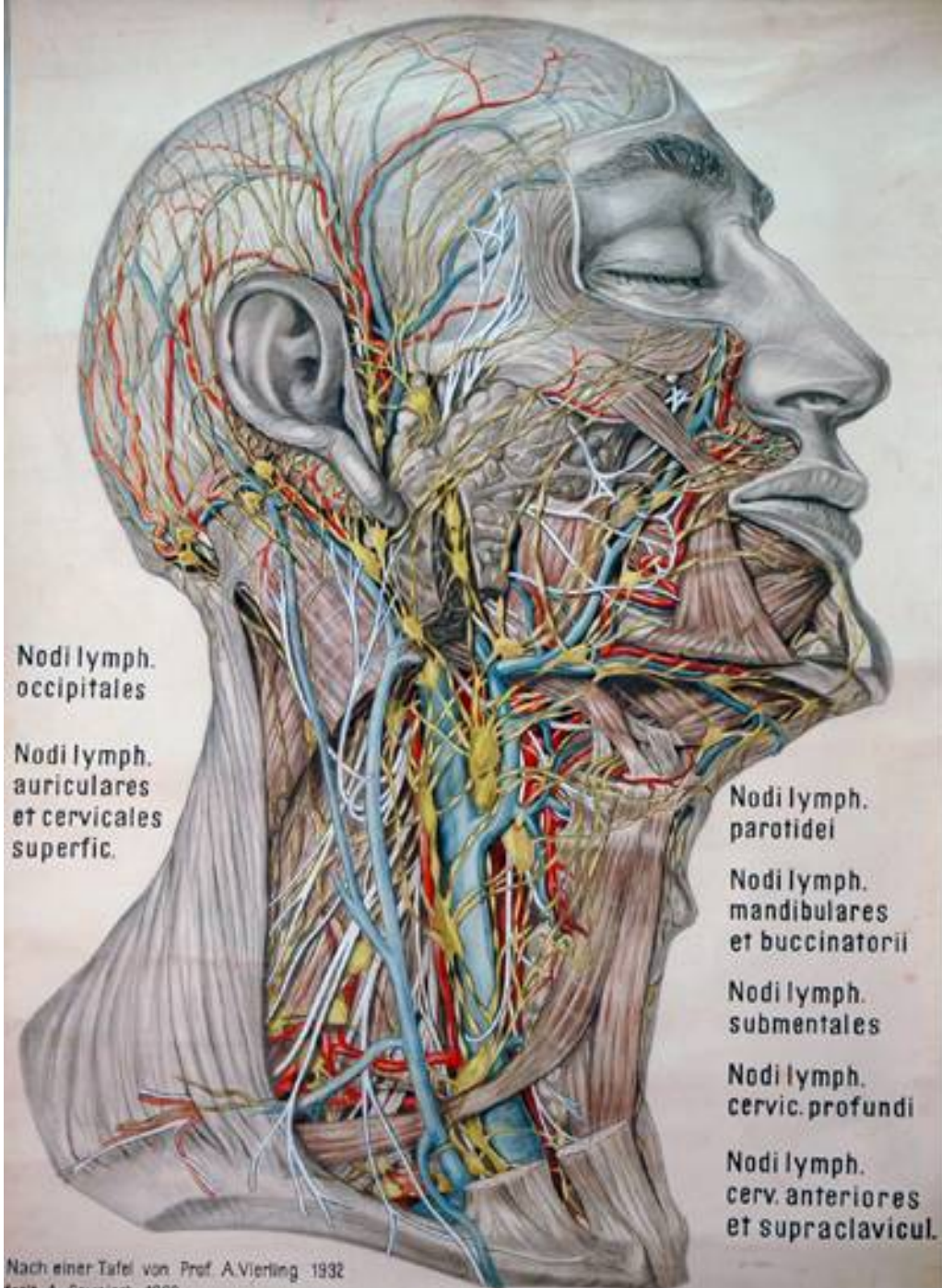
Head & Neck Surgeon's Infectiology

1. Introduction – when to grab the scalpel?

2. Anatomy

3. Surgical treatment





Nodi lymph.
occipitales

Nodi lymph.
auriculares
et cervicales
superfic.

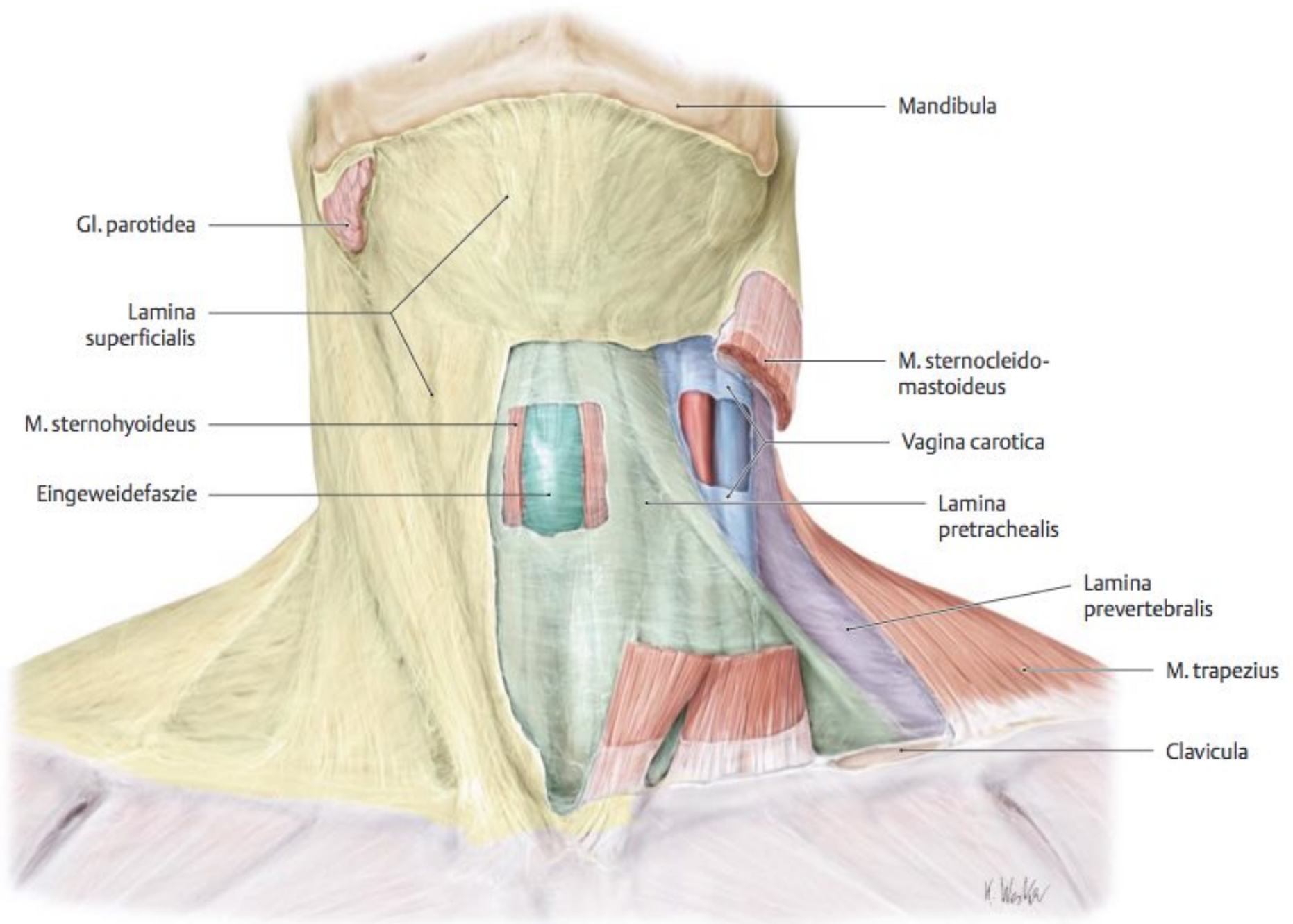
Nodi lymph.
parotidei

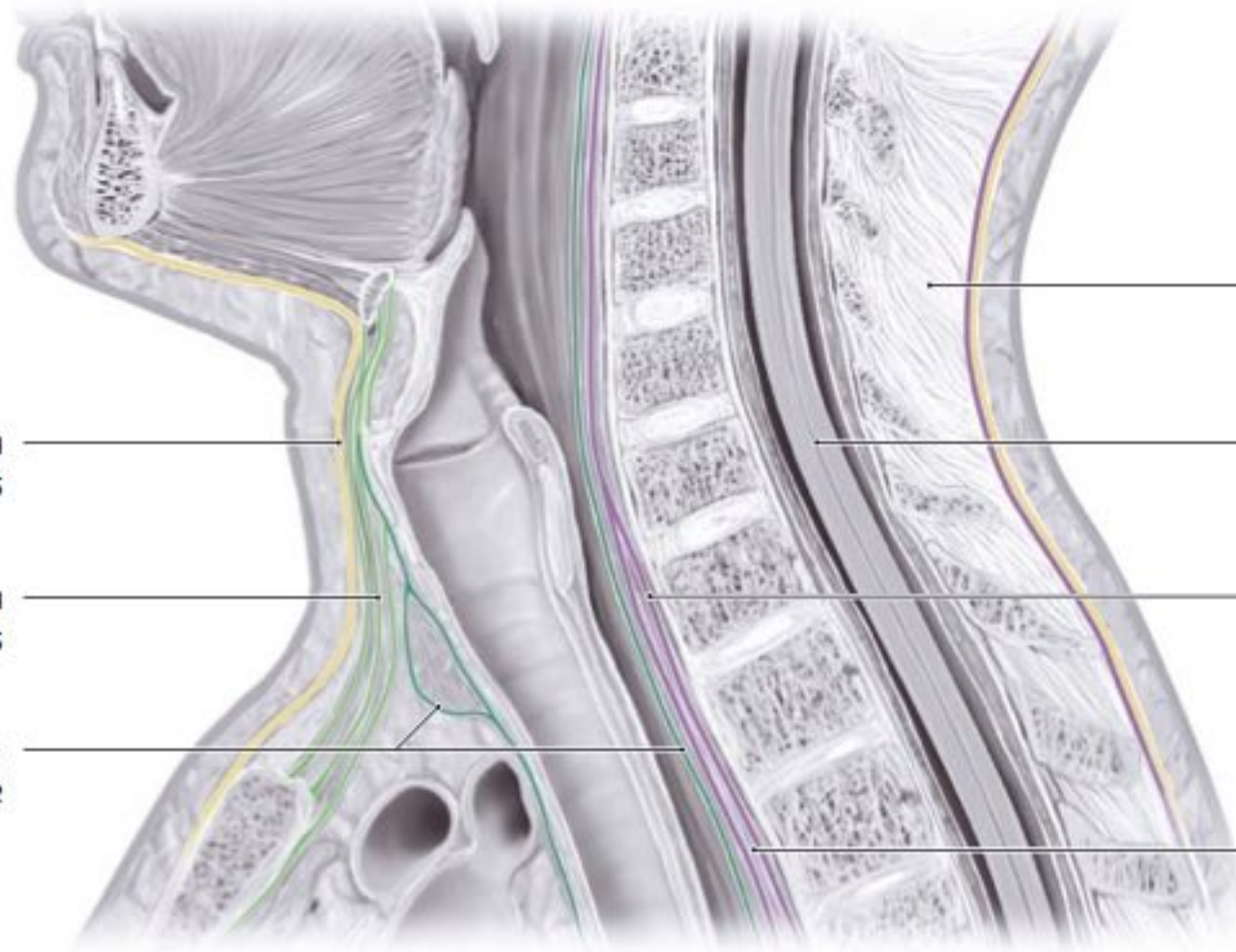
Nodi lymph.
mandibulares
et buccinatorii

Nodi lymph.
submentales

Nodi lymph.
cervic. profundi

Nodi lymph.
cerv. anteriores
et supraclavicul.





Lamina
superficialis

Lamina
pretrachealis

Eingeweide-
faszie

Lig. nuchae

Rückenmark

Lamina
prevertebralis

sog. gefährlicher
Spalt

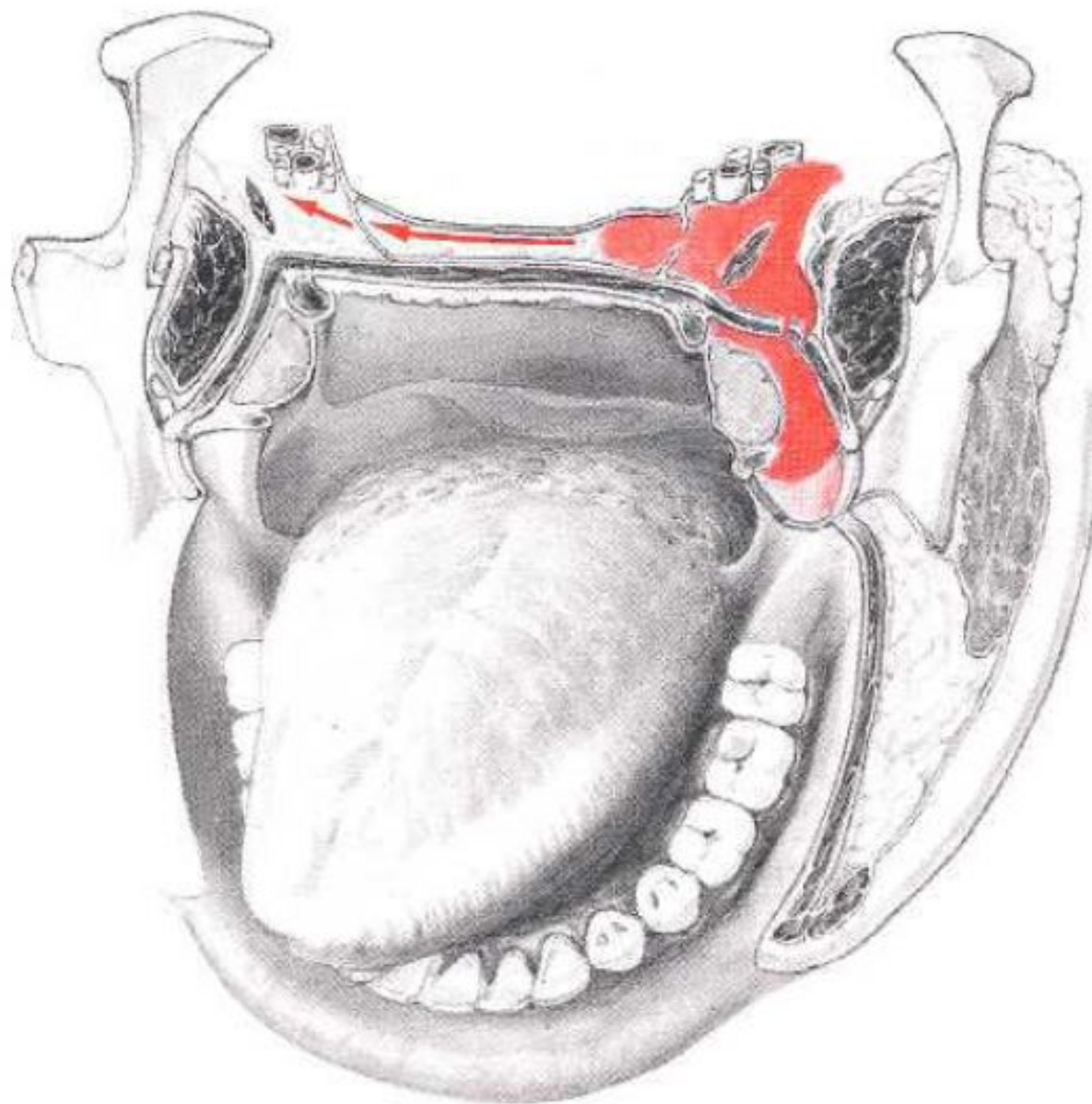
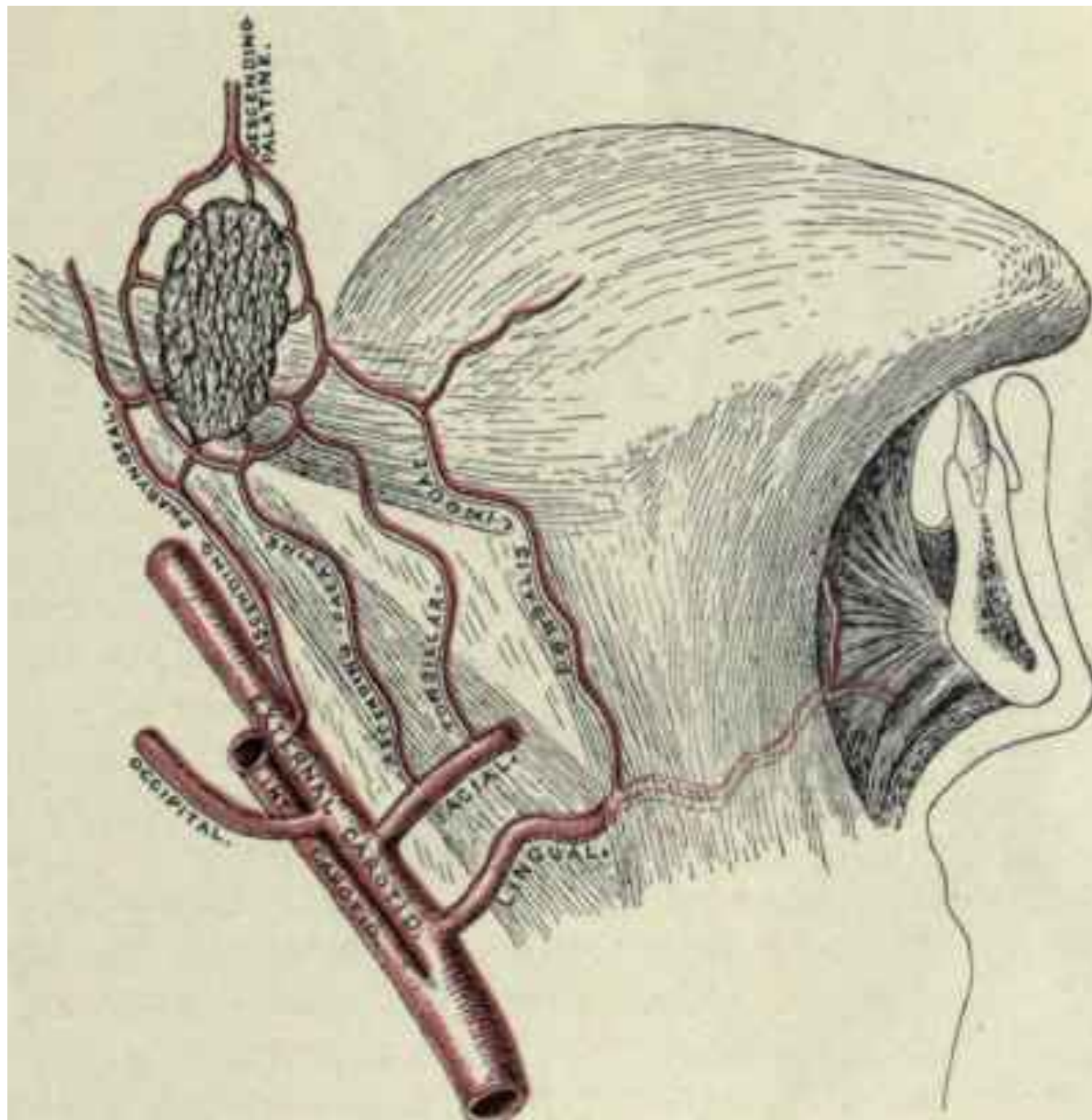


Abb. 5.53. Anatomische Verhältnisse bei Abszessen der Peri- und Retrotonsillar- sowie der Parapharyngealregion



Head & Neck Surgeon's Infectiology

1. Introduction – when to grab the scalpel?
2. Anatomy
3. Surgical treatment

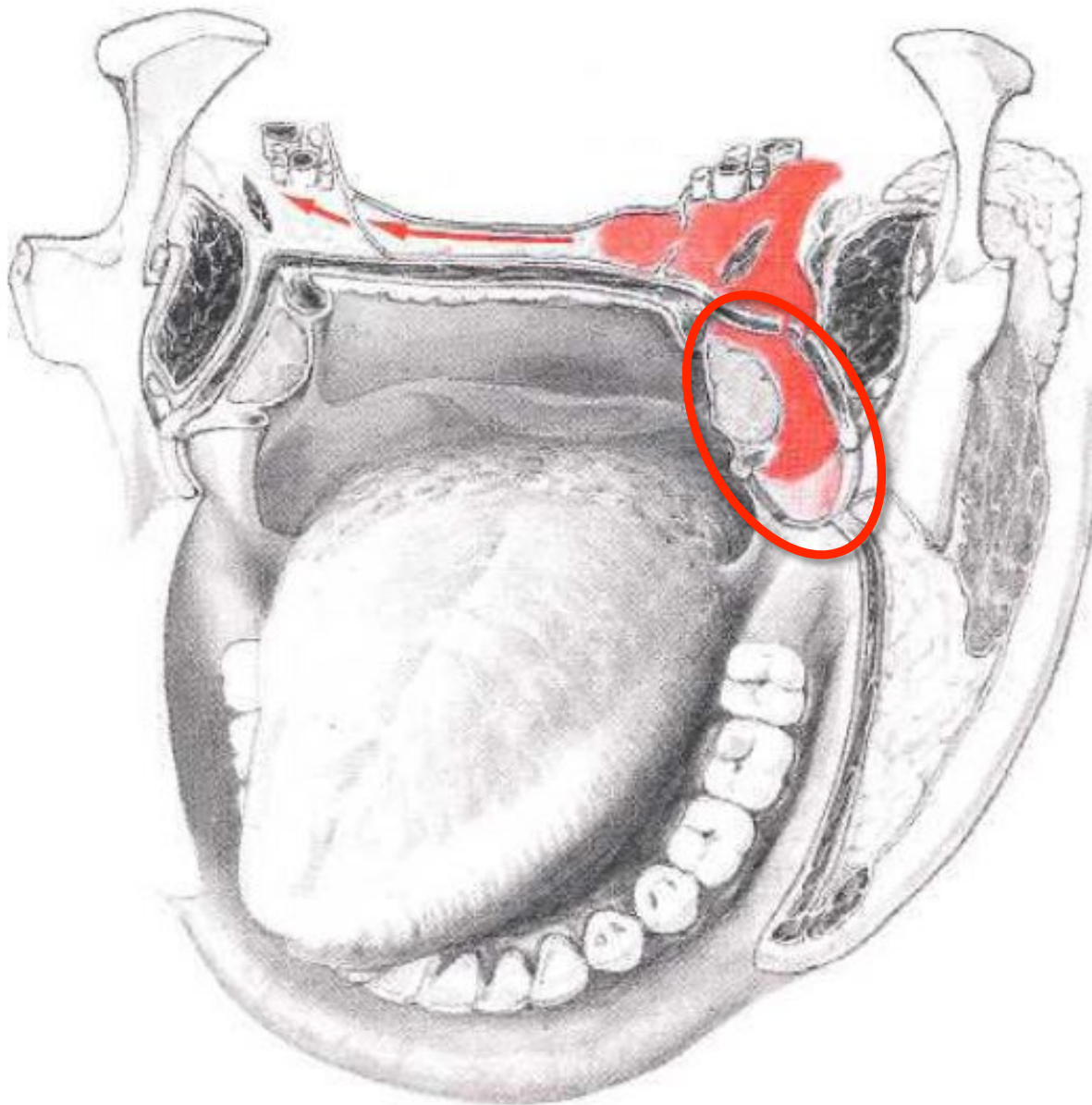
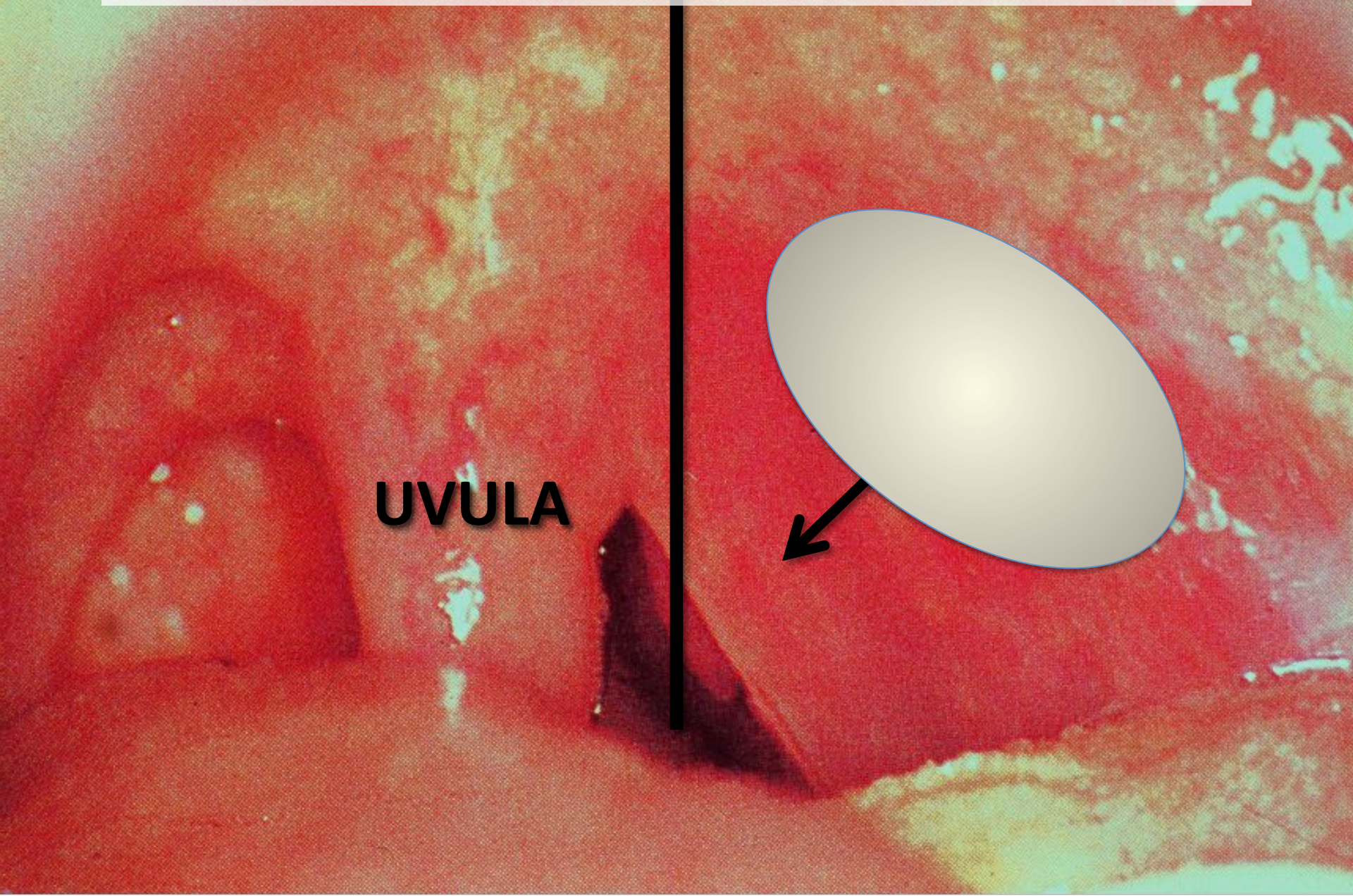
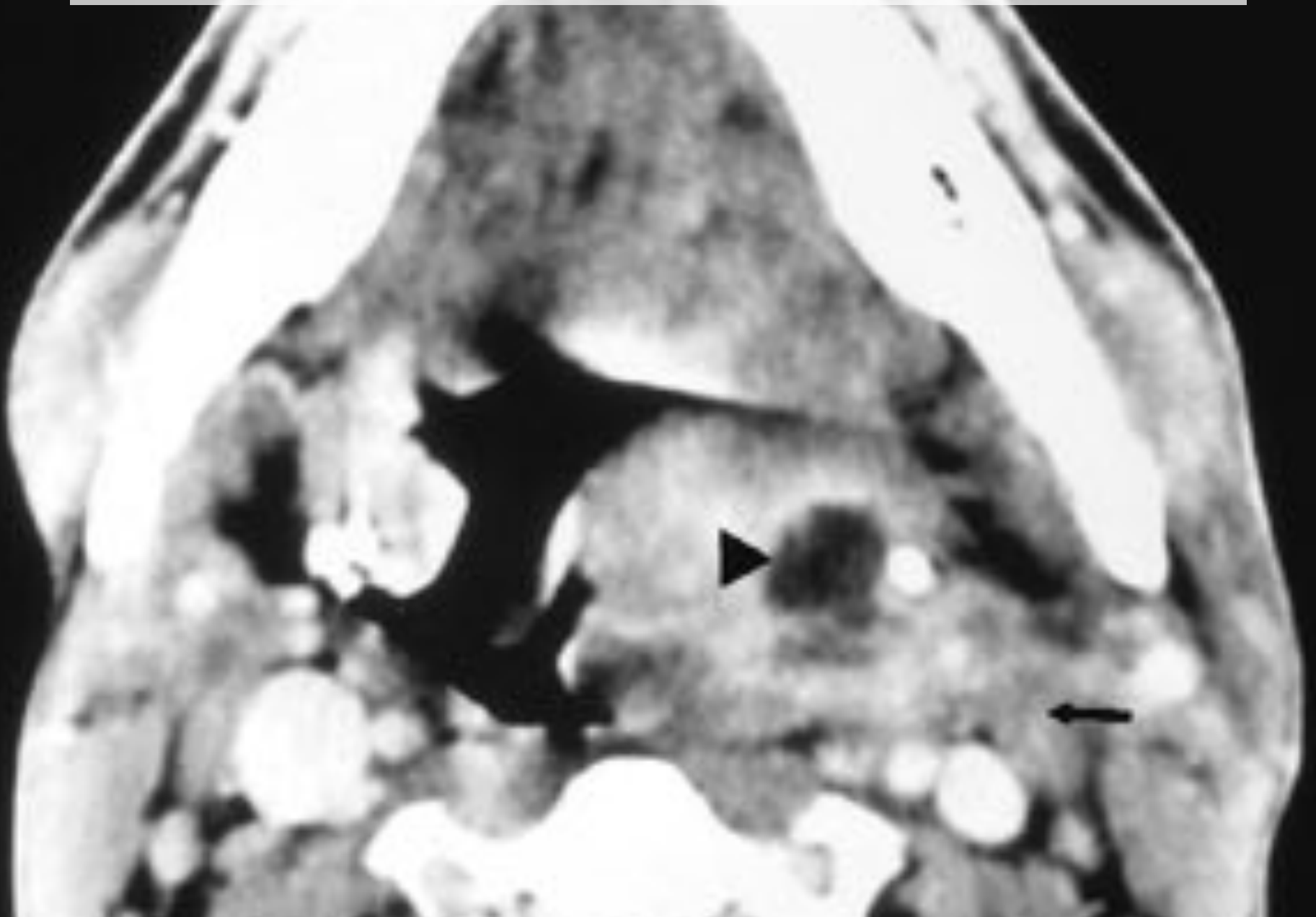


Abb. 5.53. Anatomische Verhältnisse bei Abszessen der Peri- und Retrotonsillar- sowie der Parapharyngealregion

Peritonsillar abscess

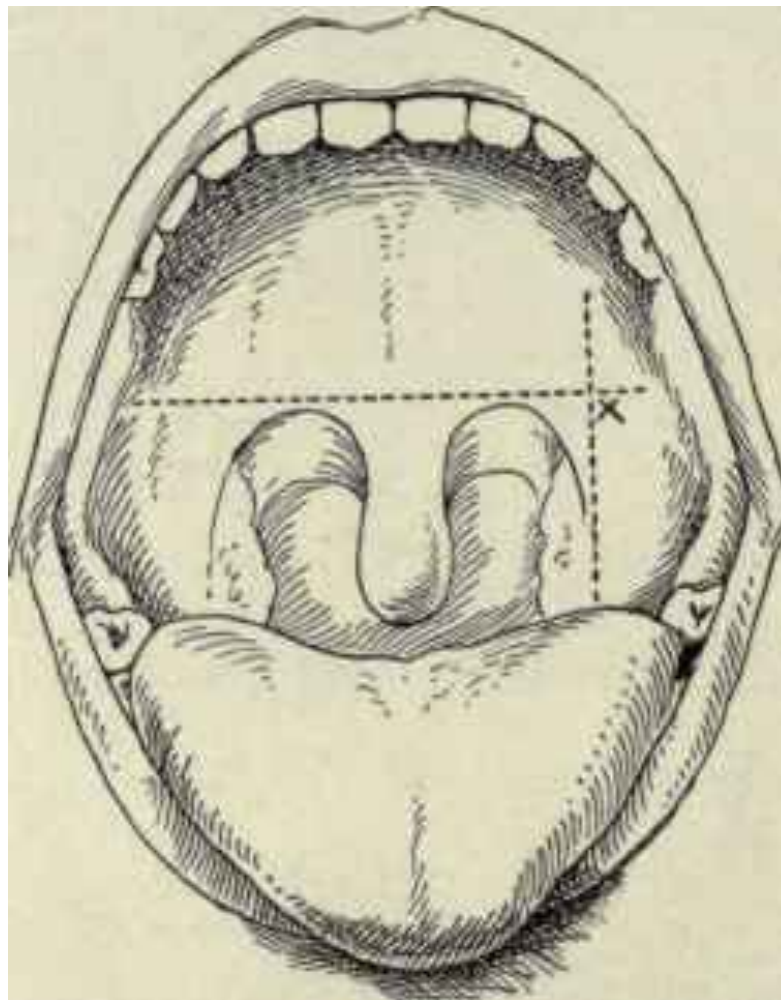


Peritonsillar abscess

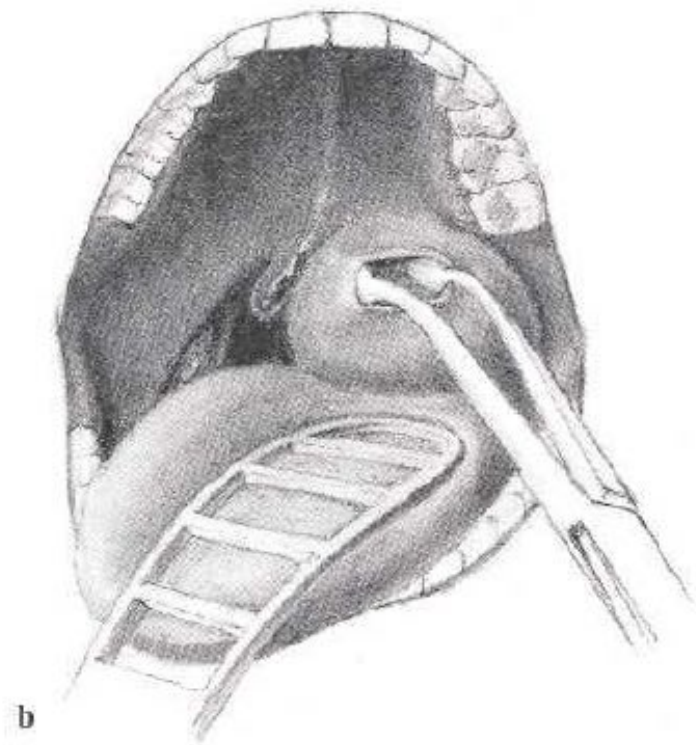
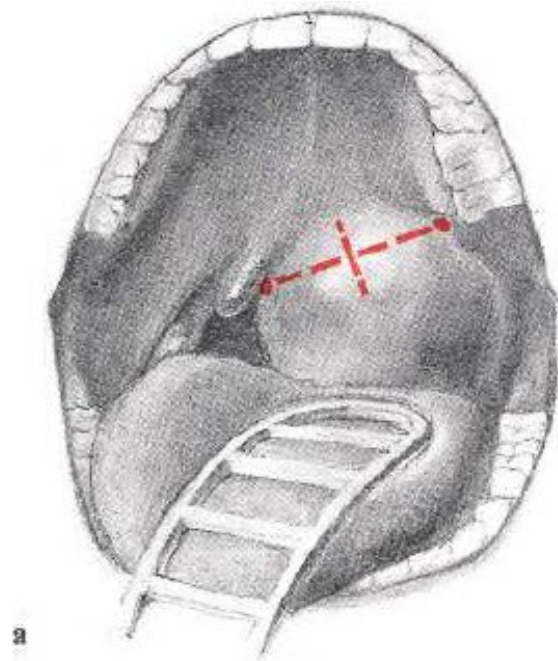


Peritonsillar abscess

- Normally unilateral after tonsillitis (even under antibiotic therapy)
- Agglutination, drooling, trismus
- Incision in LA & daily rinsing with antiseptic
- Alternative: Puncture, often repeated
- Abszess-tonsillektomy (young children)
- Antibiotics
- After incision or puncture, tonsillektomy is often recommended after 3 months



Point of puncture for tonsillar abscess. "If an imaginary horizontal line is drawn across the base of the uvula, and another vertically along the anterior faucial pillar, they will intersect at a point overlying the supratonsillar fossa. Just external to this is the best point for opening a quinsy." - St. Clair Thomson, M.D., Brit. M. J., March 25, **1905**, p. 645.



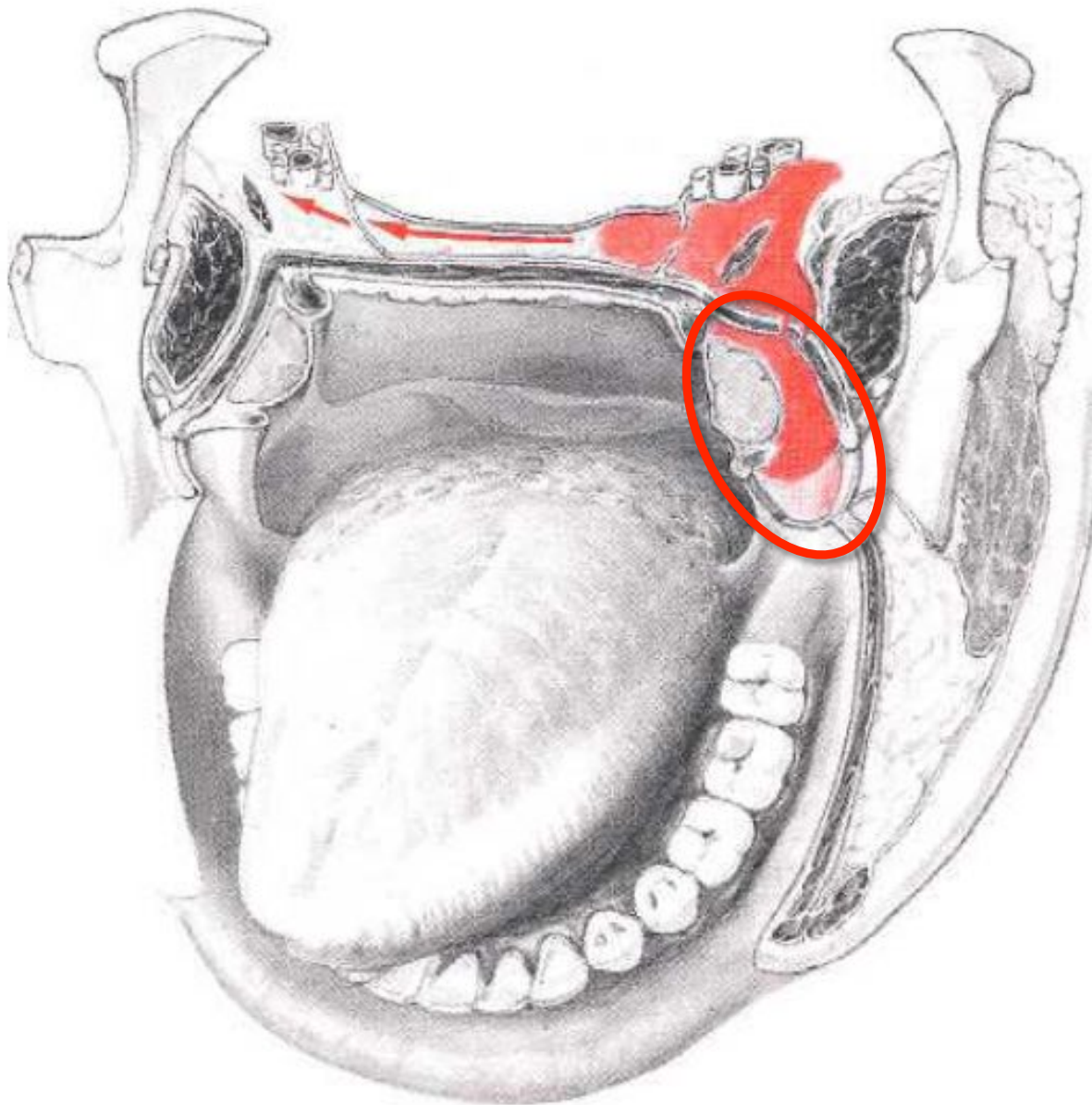


Abb. 5.53. Anatomische Verhältnisse bei Abszessen der Peri- und Retrotonsillar- sowie der Parapharyngealregion

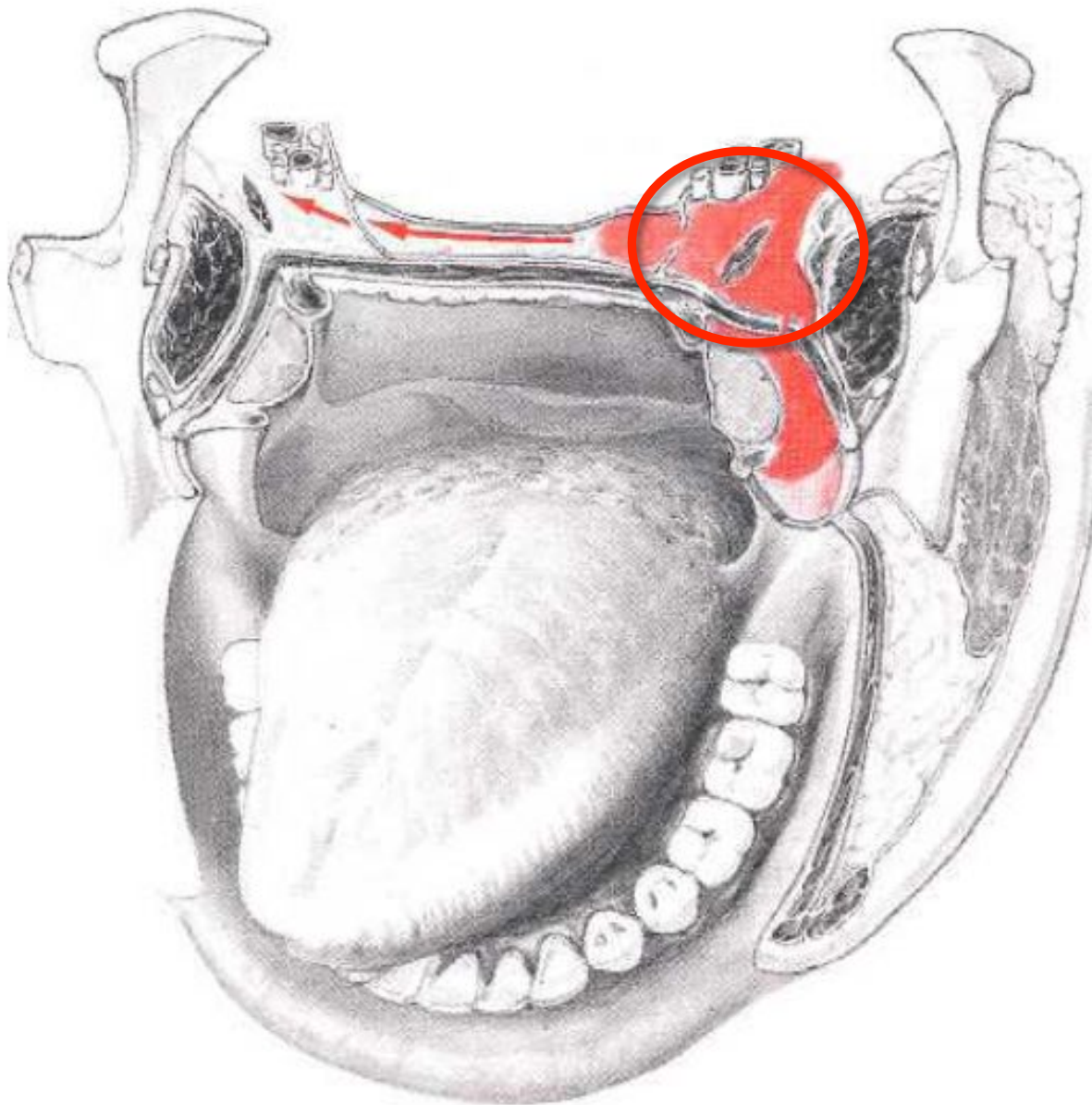
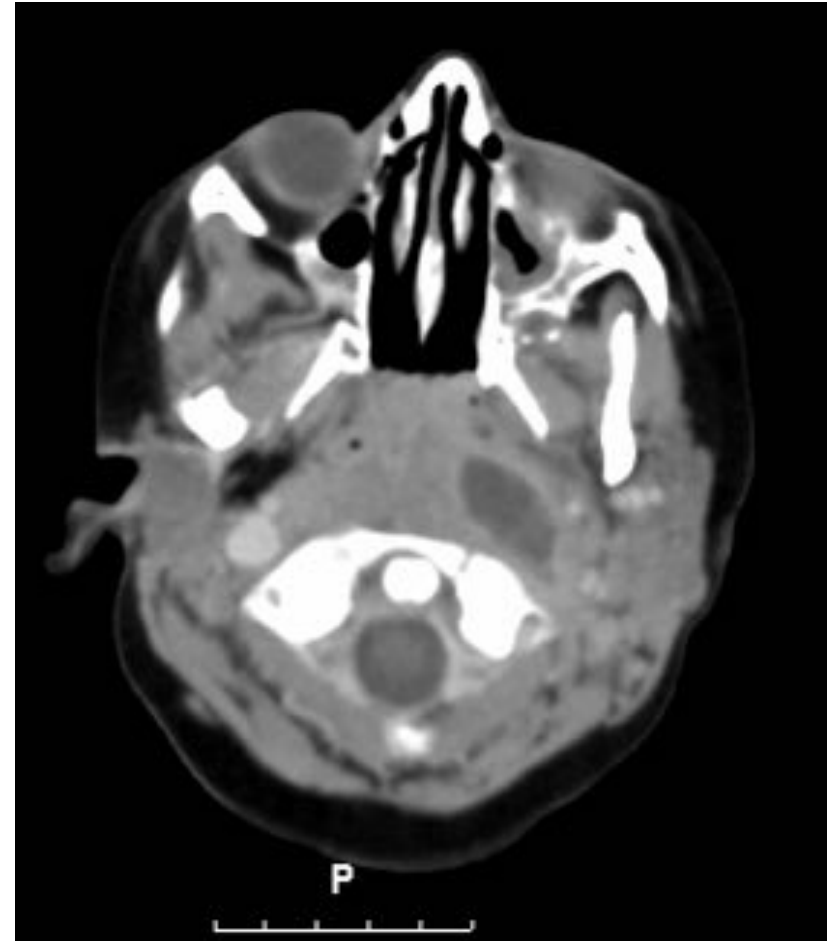
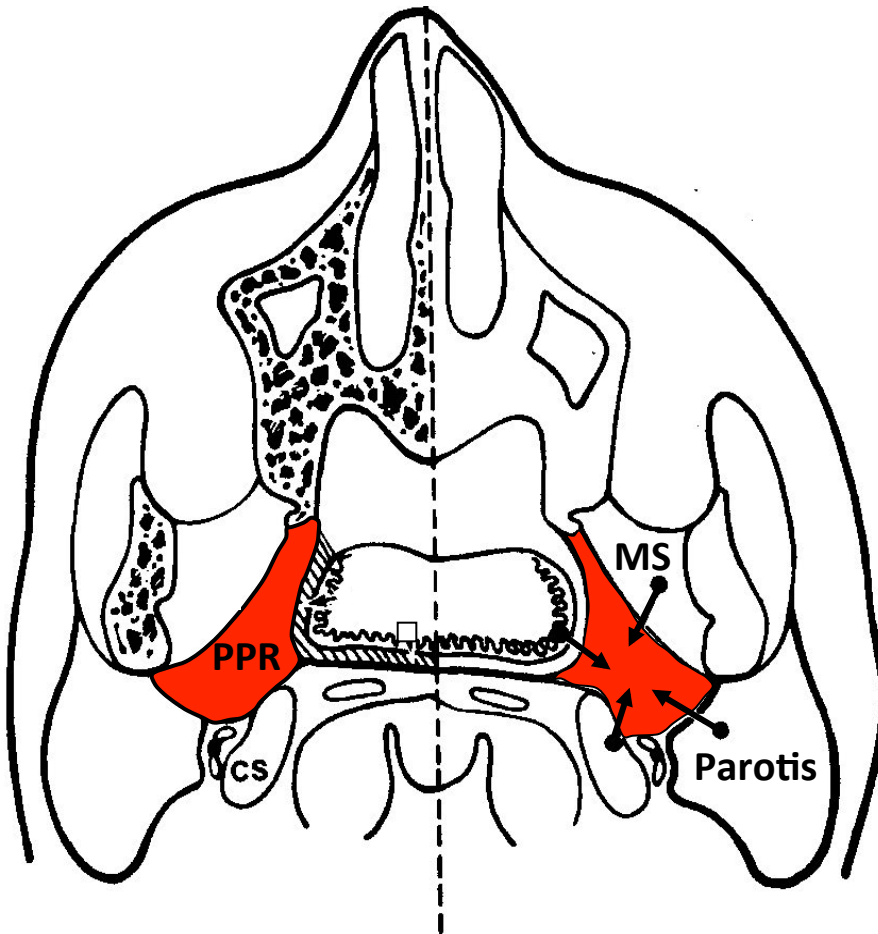
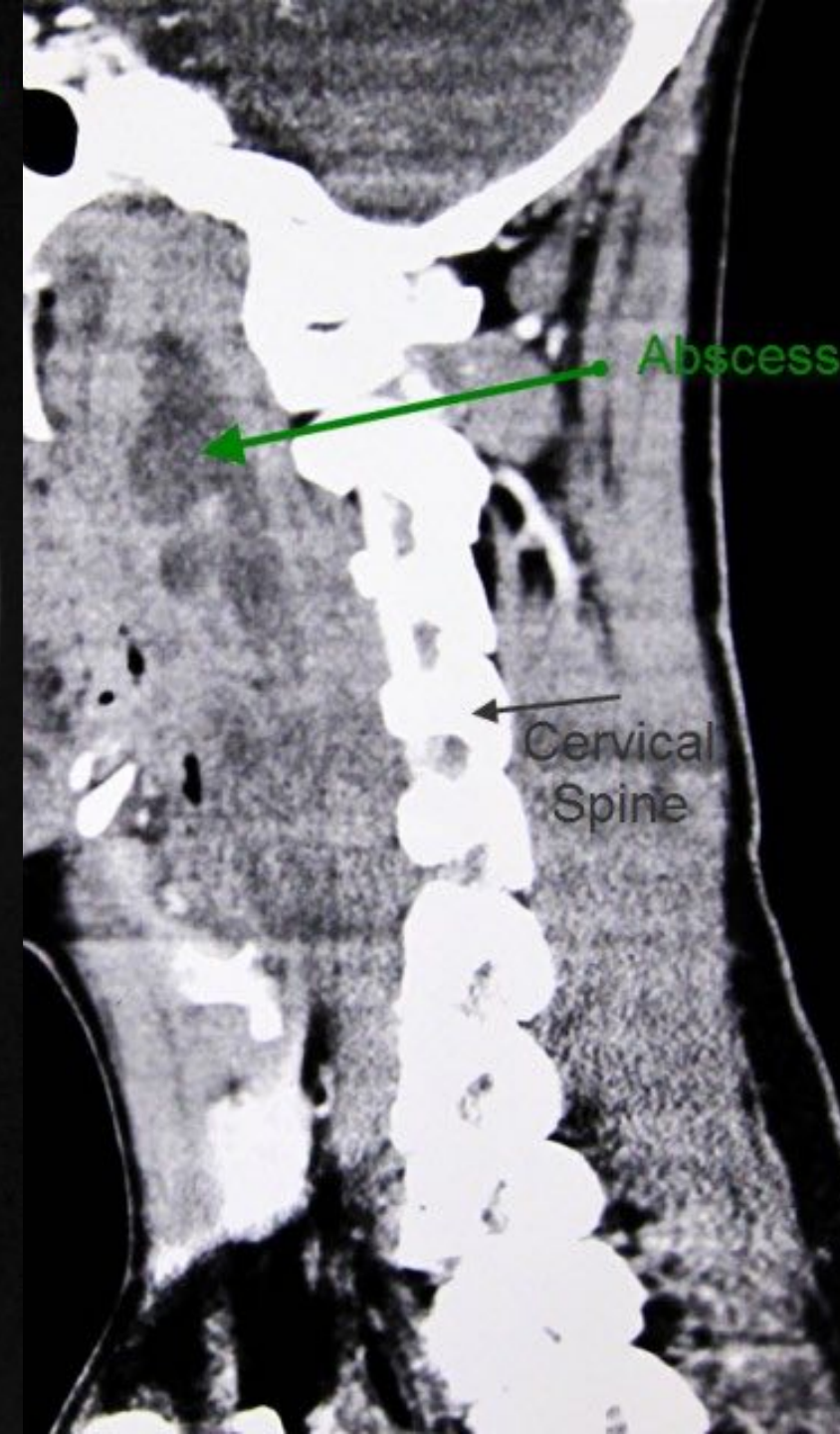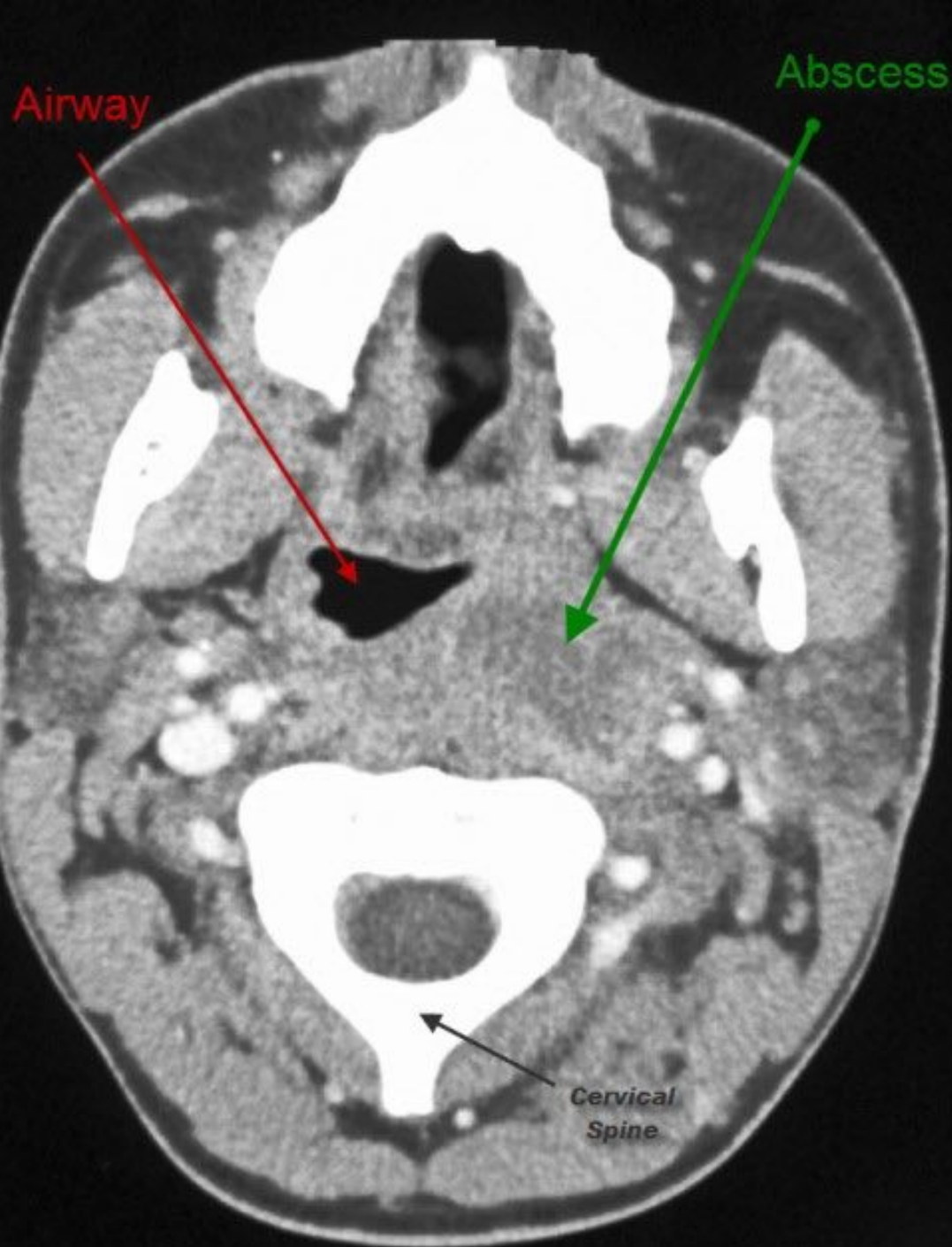


Abb. 5.53. Anatomische Verhältnisse bei Abszessen der Peri- und Retrotonsillar- sowie der Parapharyngealregion

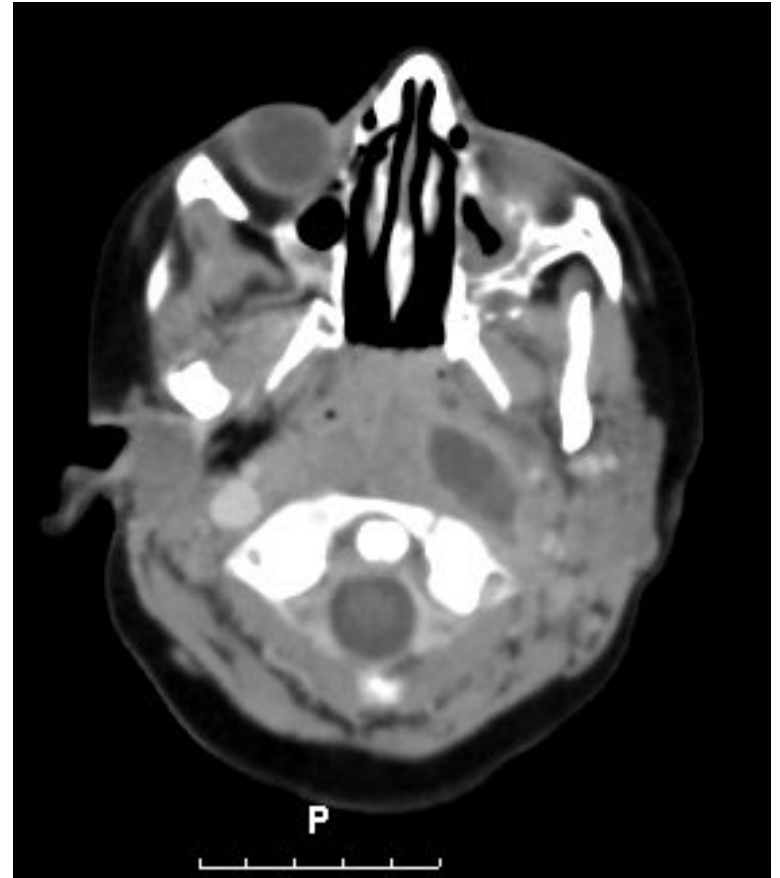Parapharyngeal abscess





Parapharyngeal abscess

- Older children
- TRISMUS (Mm Pterigoidei)
- CT/MR
- Drainage +/- TE
- i.v. antibiotic therapy



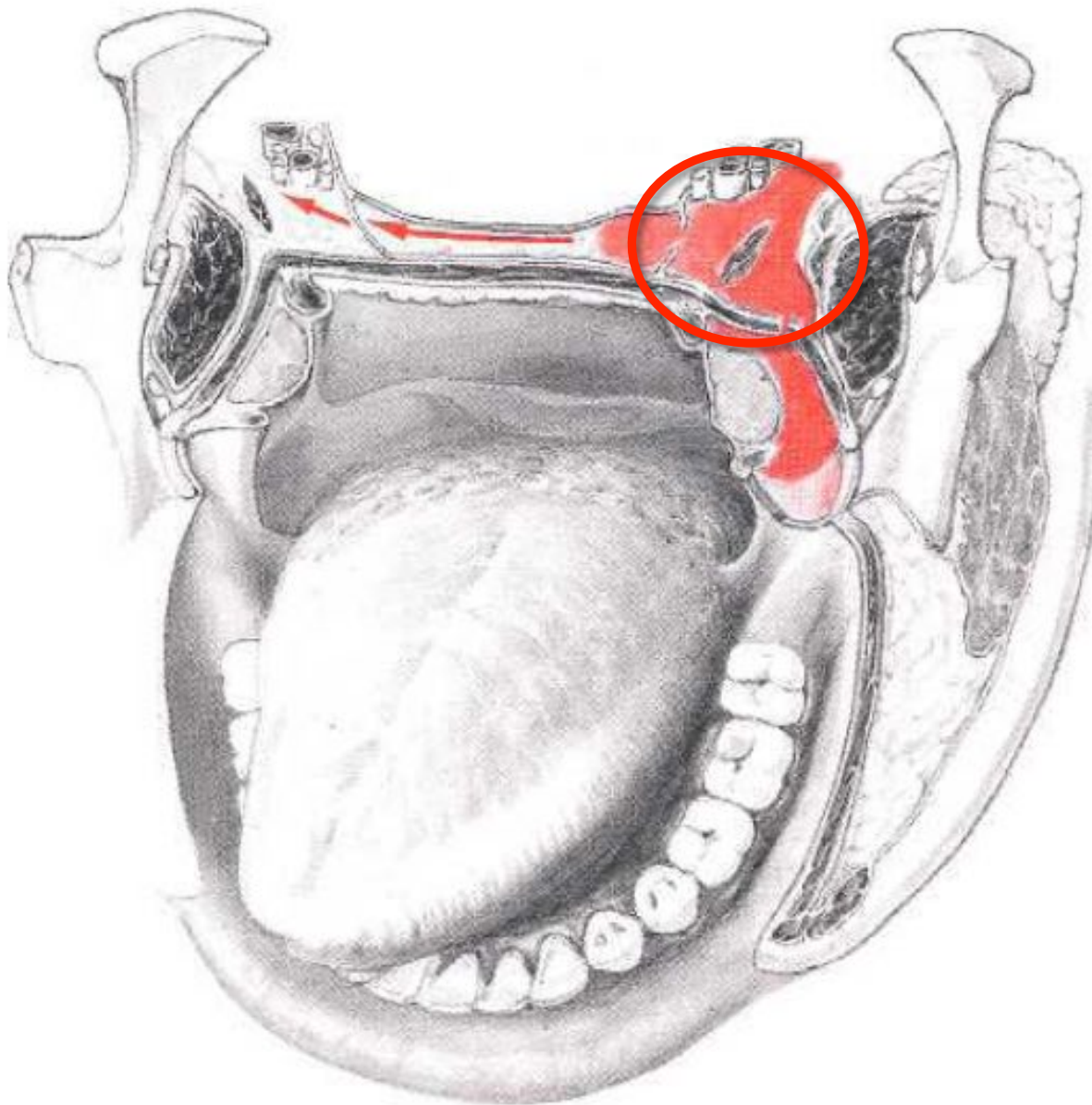


Abb. 5.53. Anatomische Verhältnisse bei Abszessen der Peri- und Retrotonsillar- sowie der Parapharyngealregion

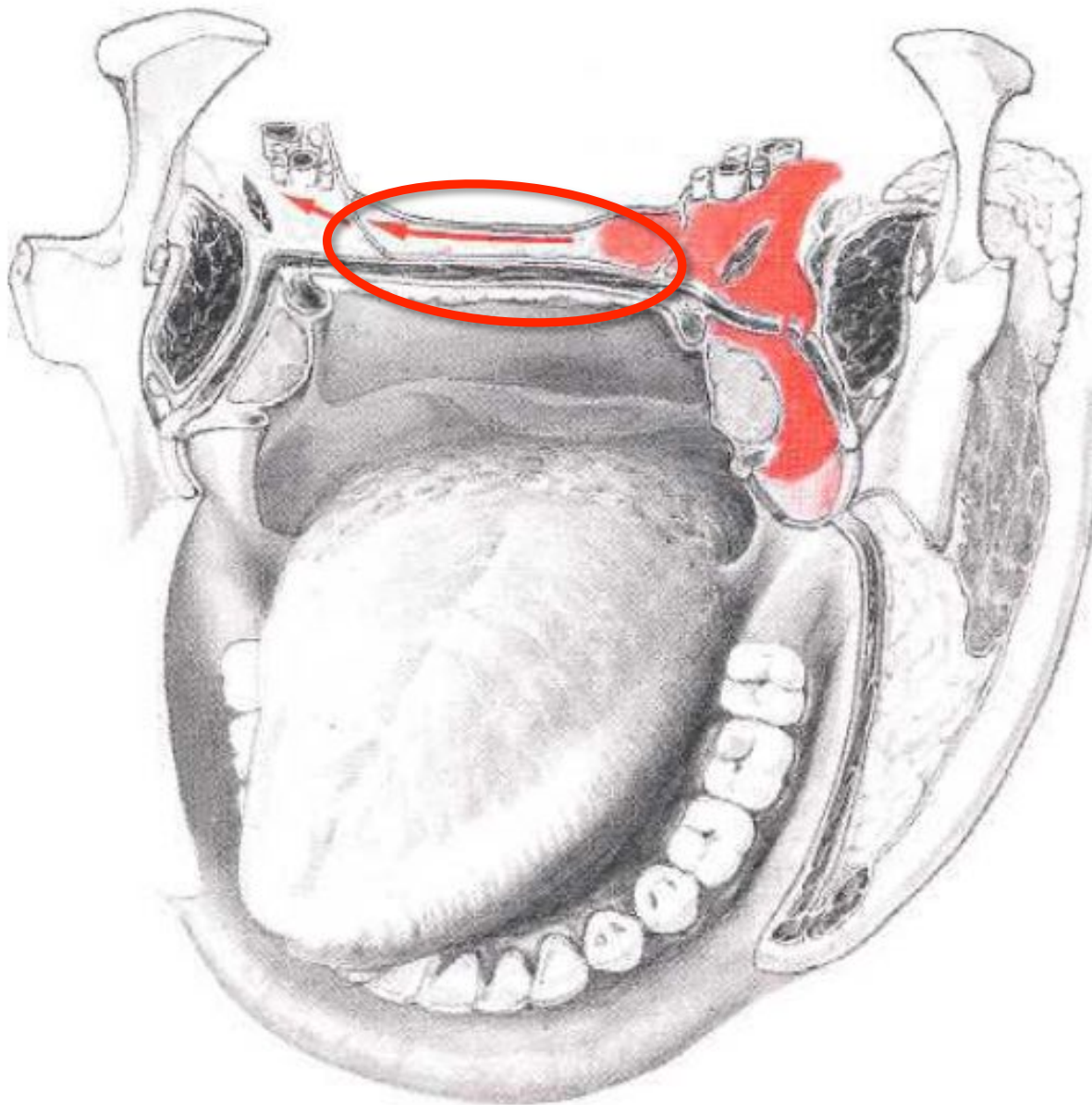
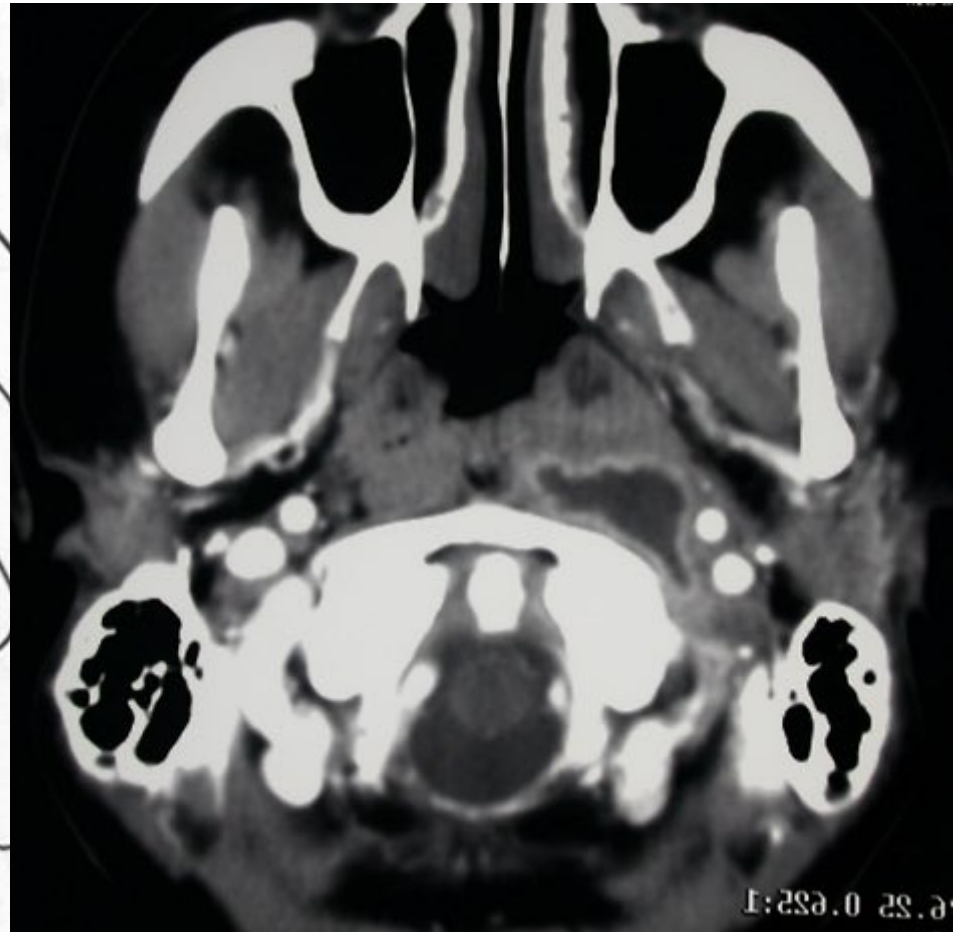
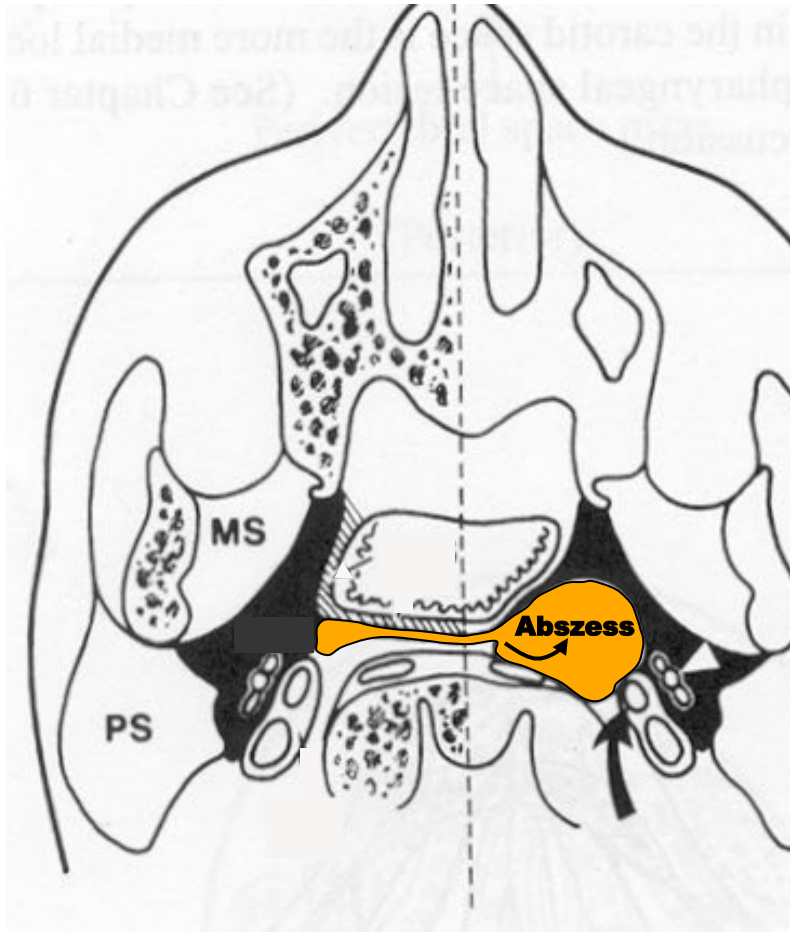


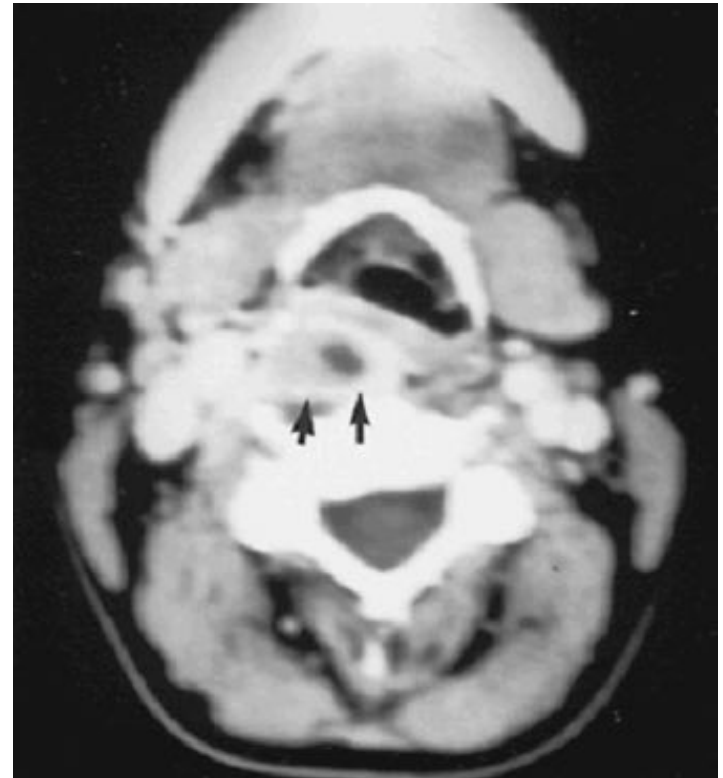Abb. 5.53. Anatomische Verhältnisse bei Abszessen der Peri- und Retrotonsillar- sowie der Parapharyngealregion

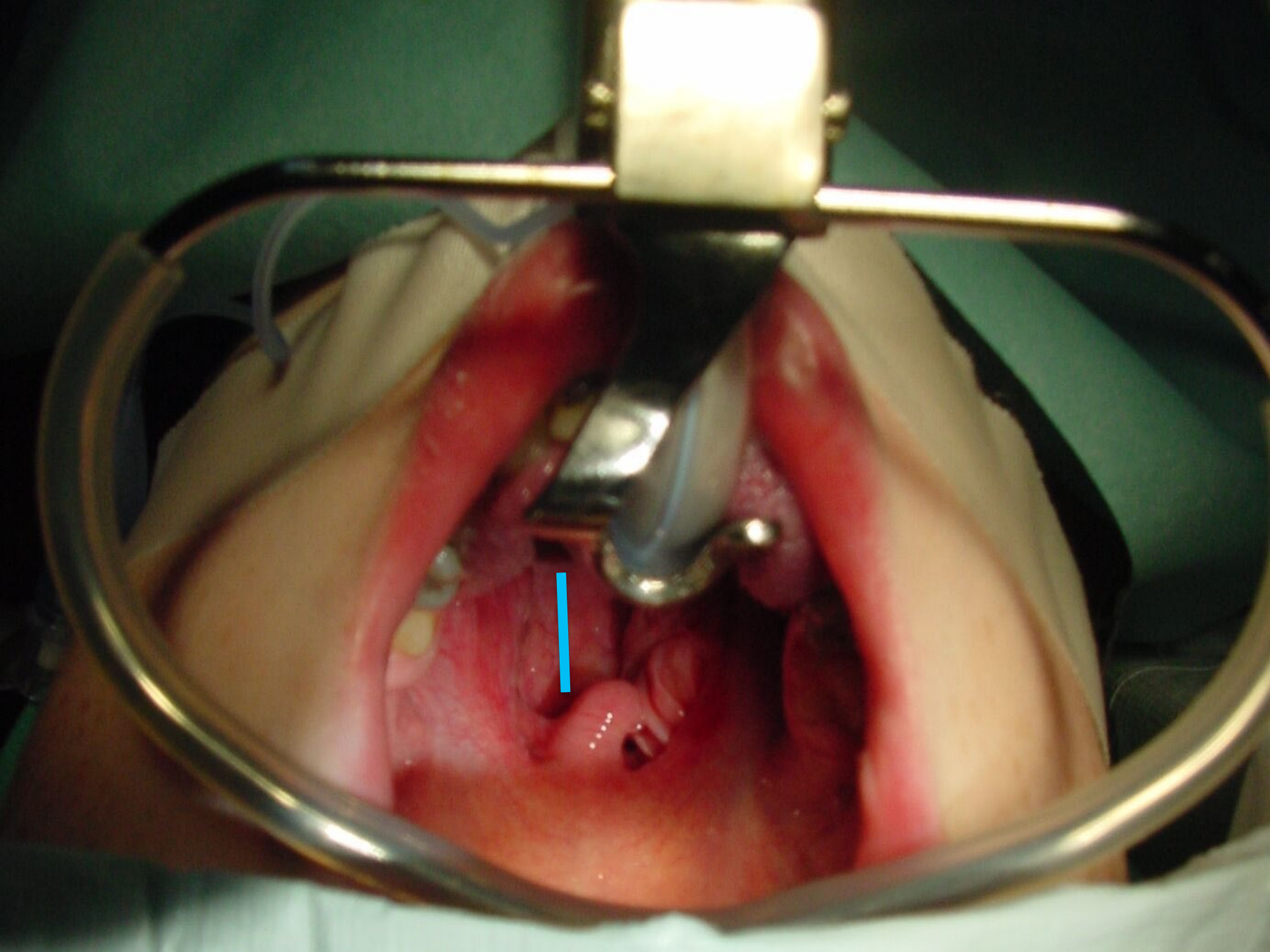
Retropharyngeal abscess

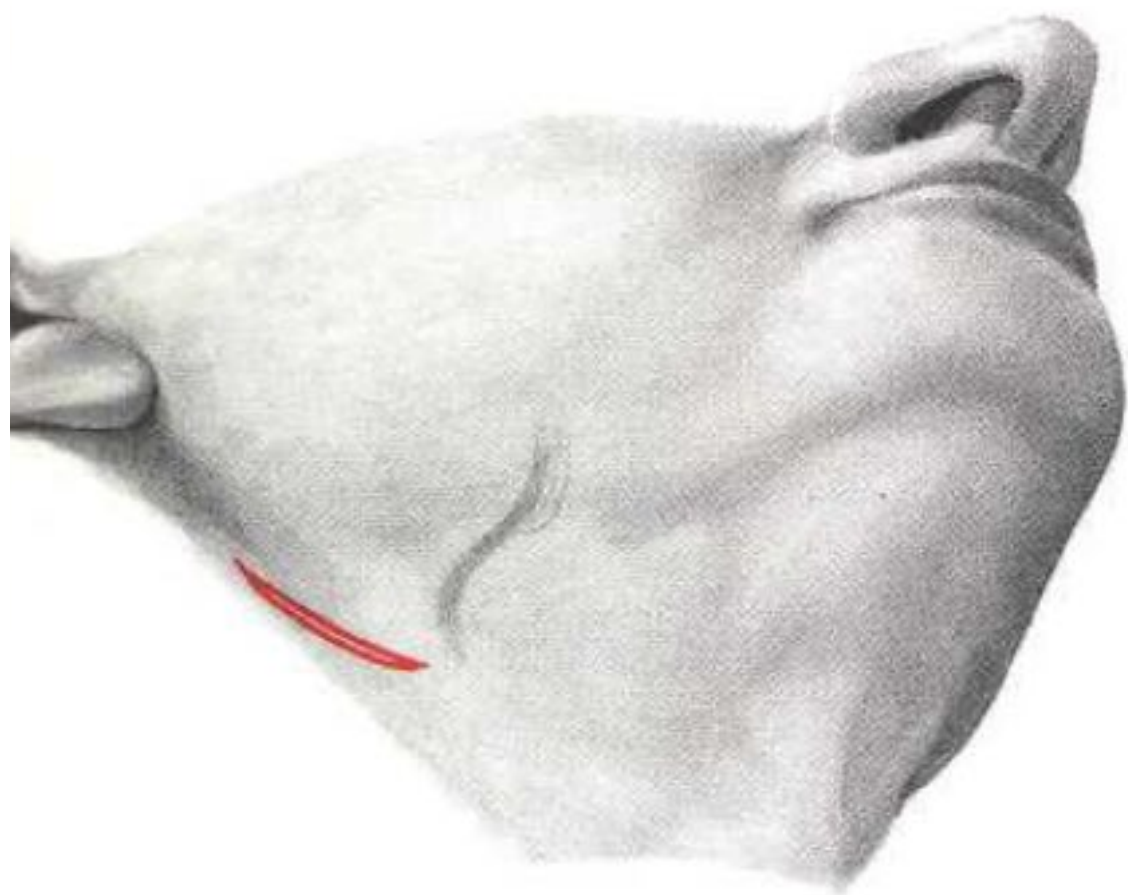


Retropharyngeal abscess

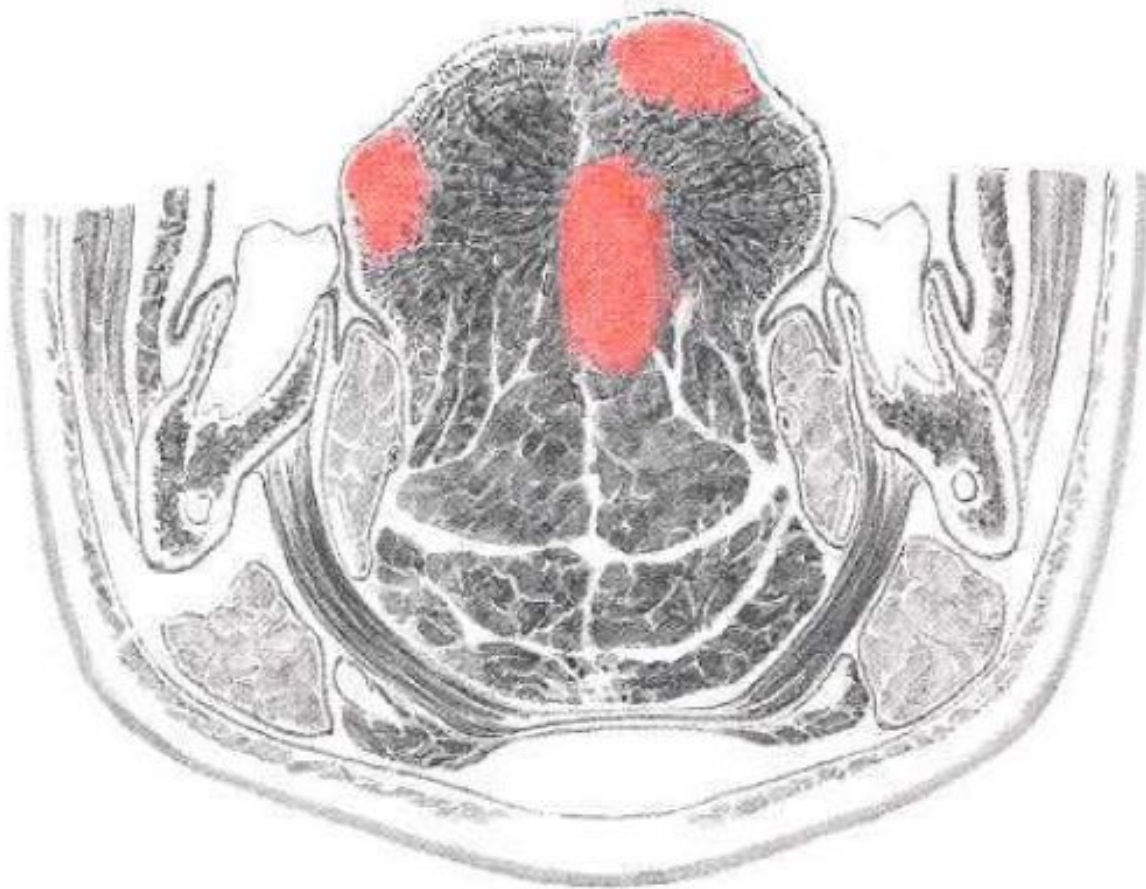
- Children
- Torticollis, dysphagia, dyspnoea
- Bulging of dorsal pharyngeal wall
- CT/MR
- Drainage (peroral/cervical)
- i.v. antibiotic therapy

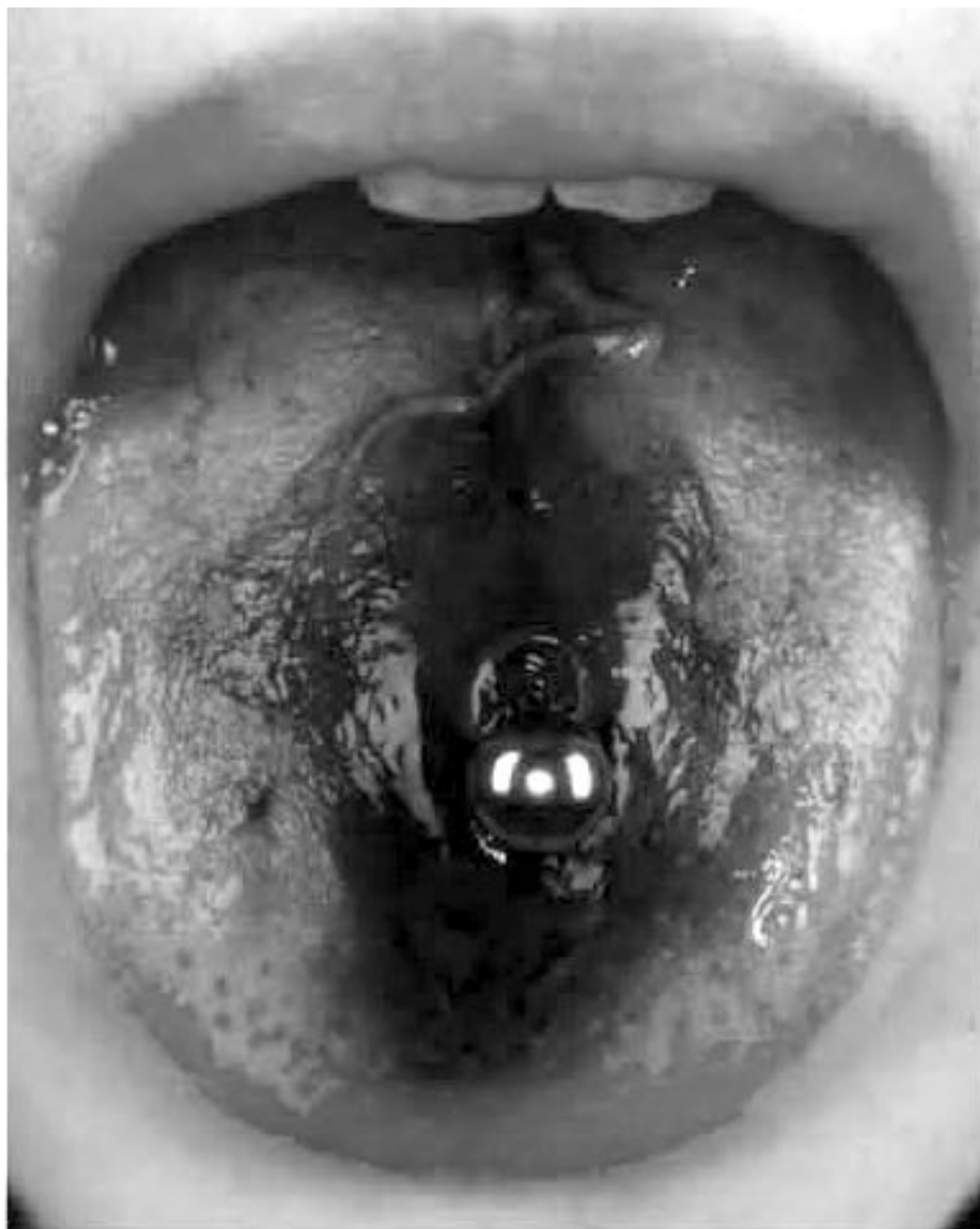

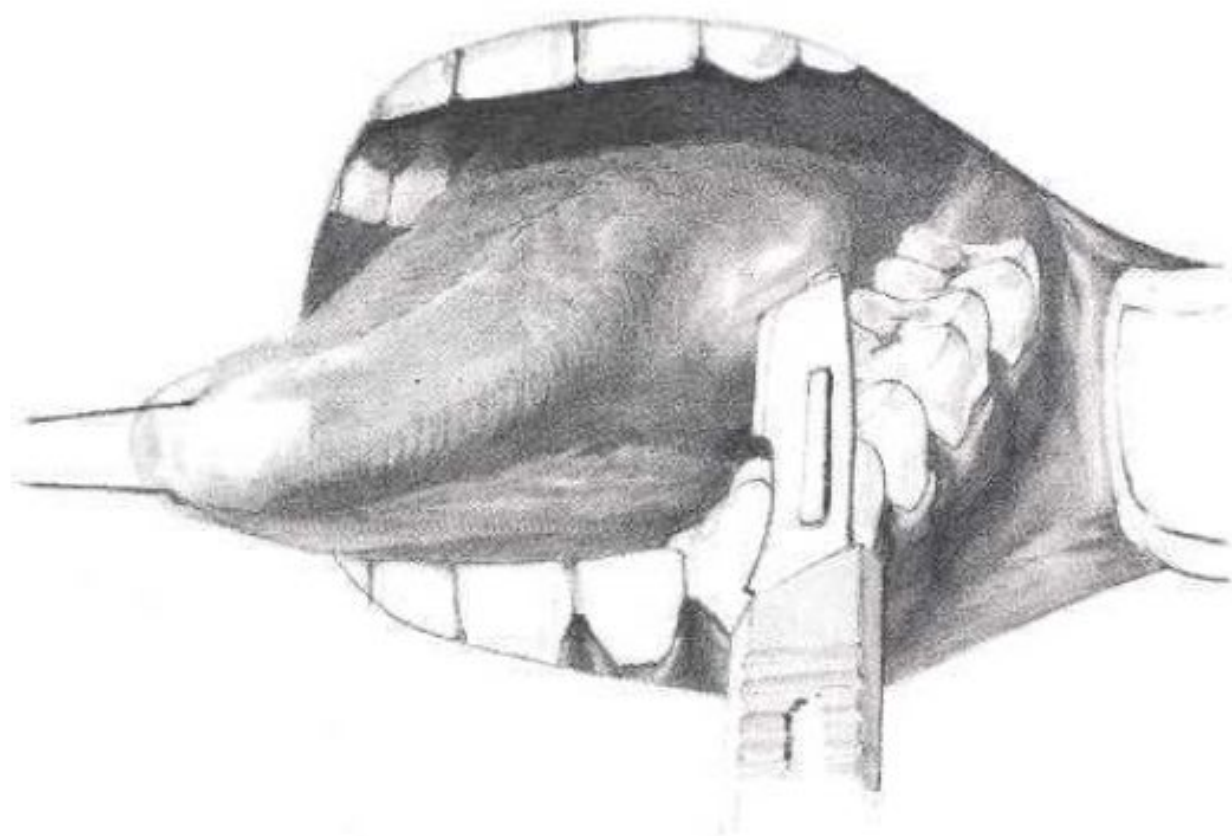




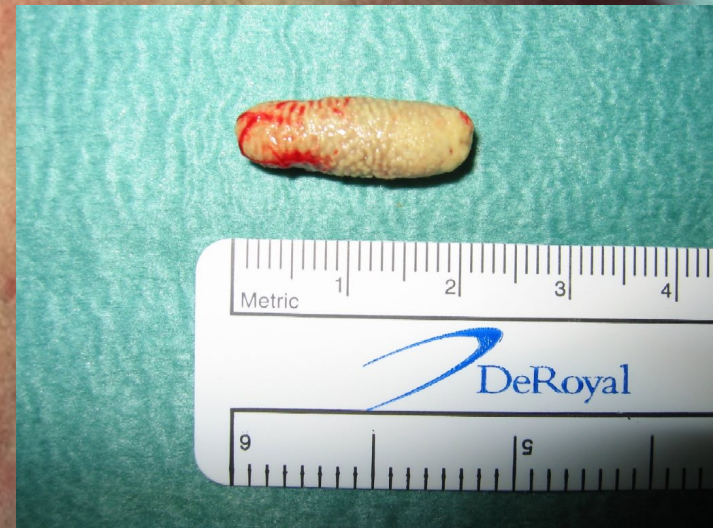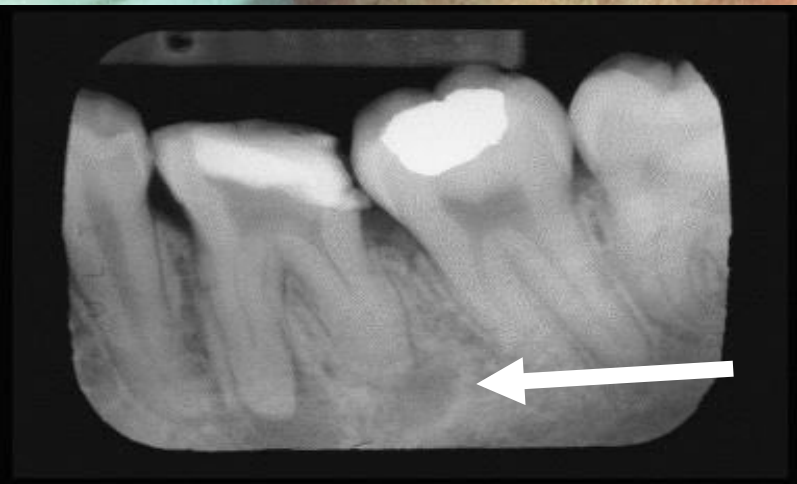
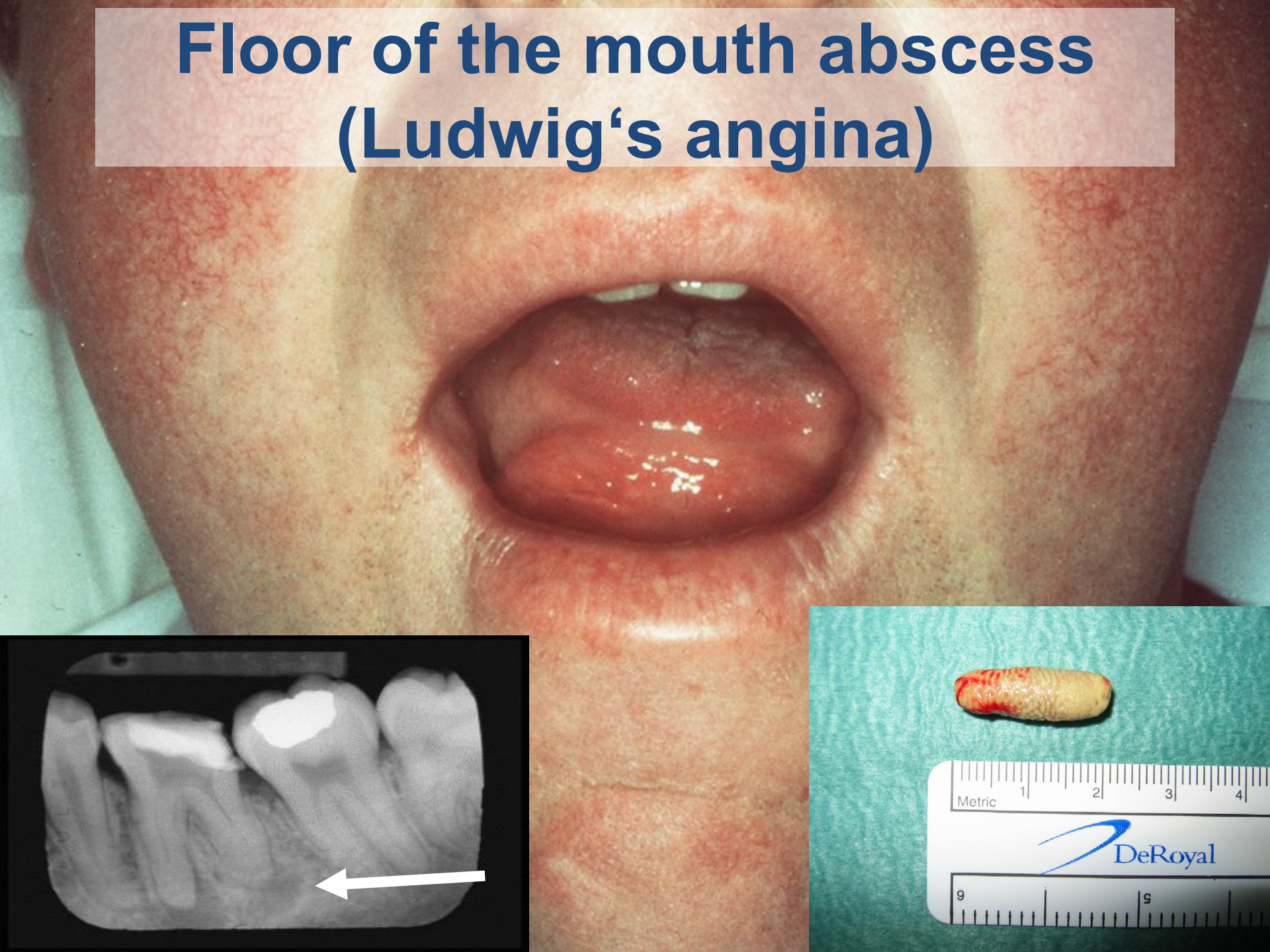
Tongue abscess

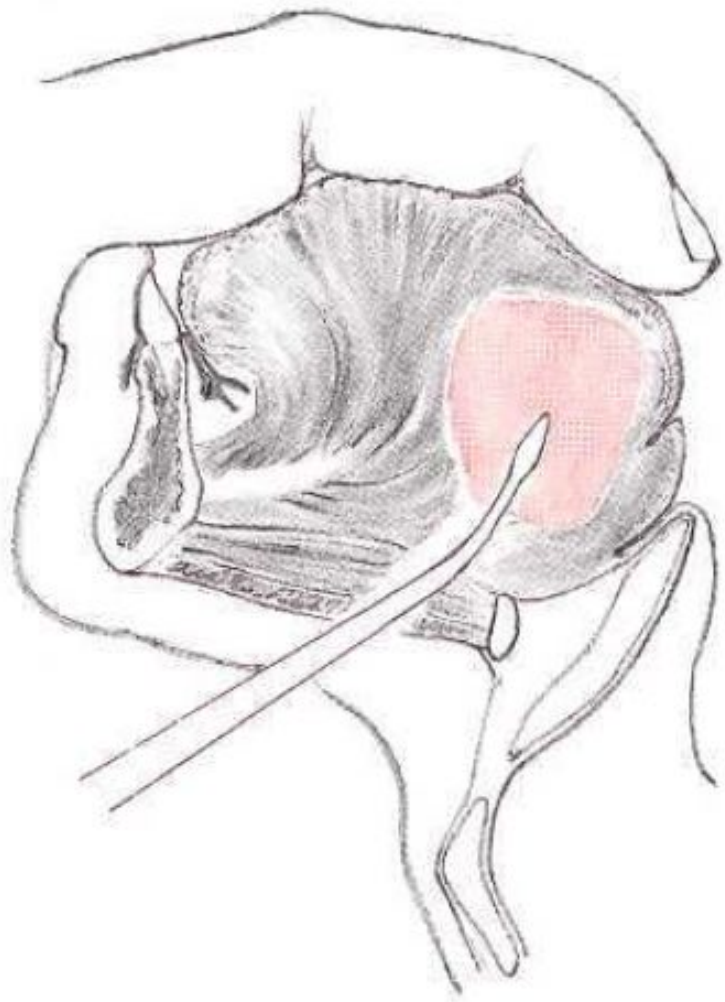




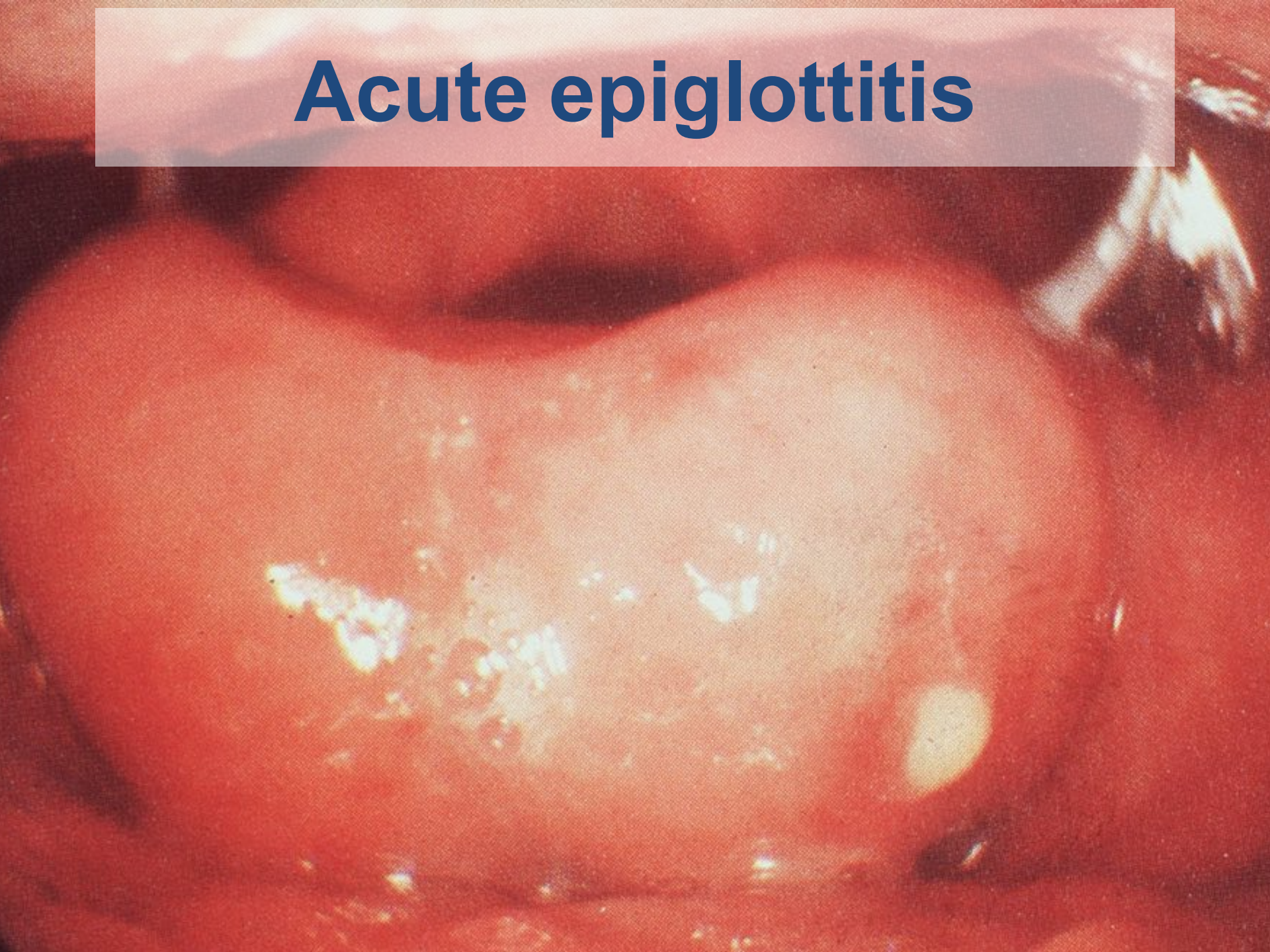


Floor of the mouth abscess (Ludwig's angina)



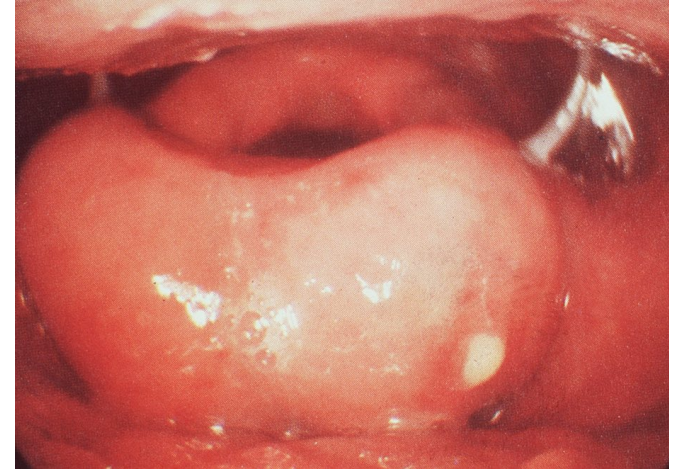


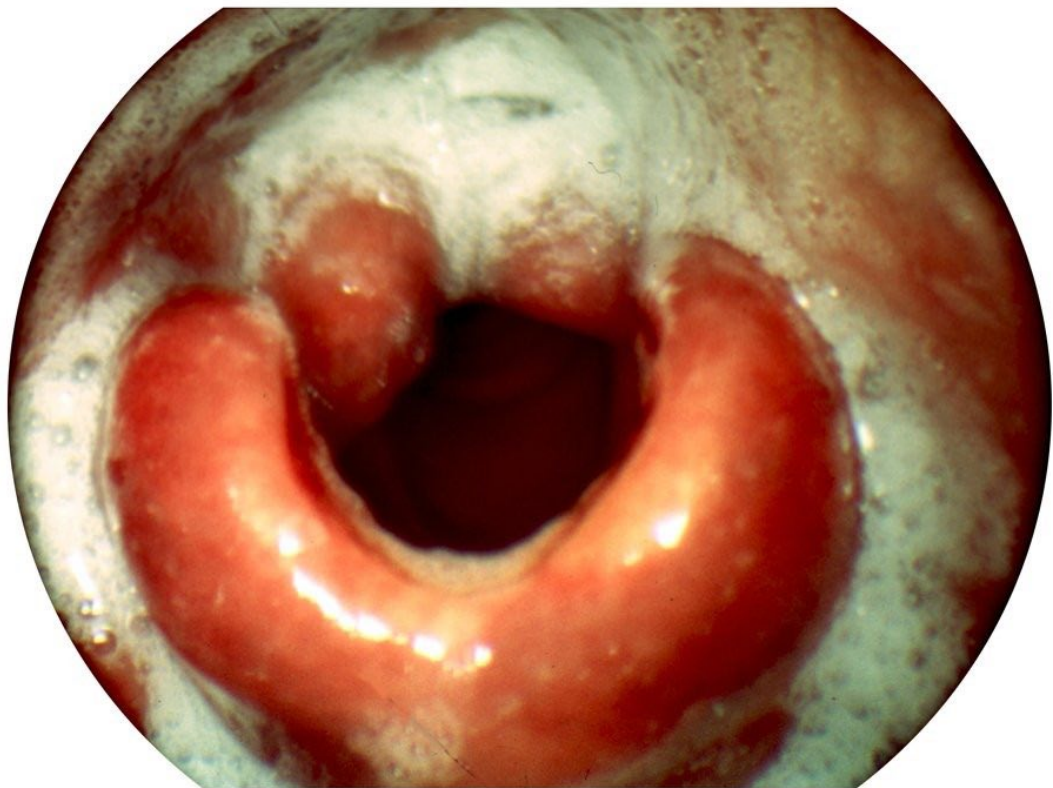
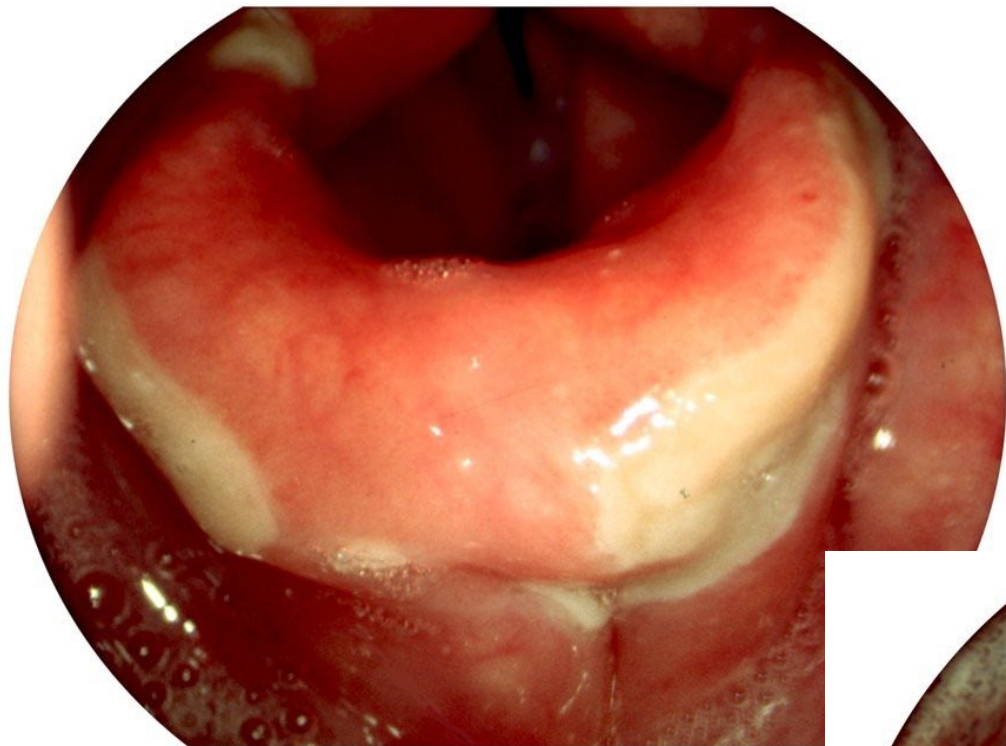Acute epiglottitis



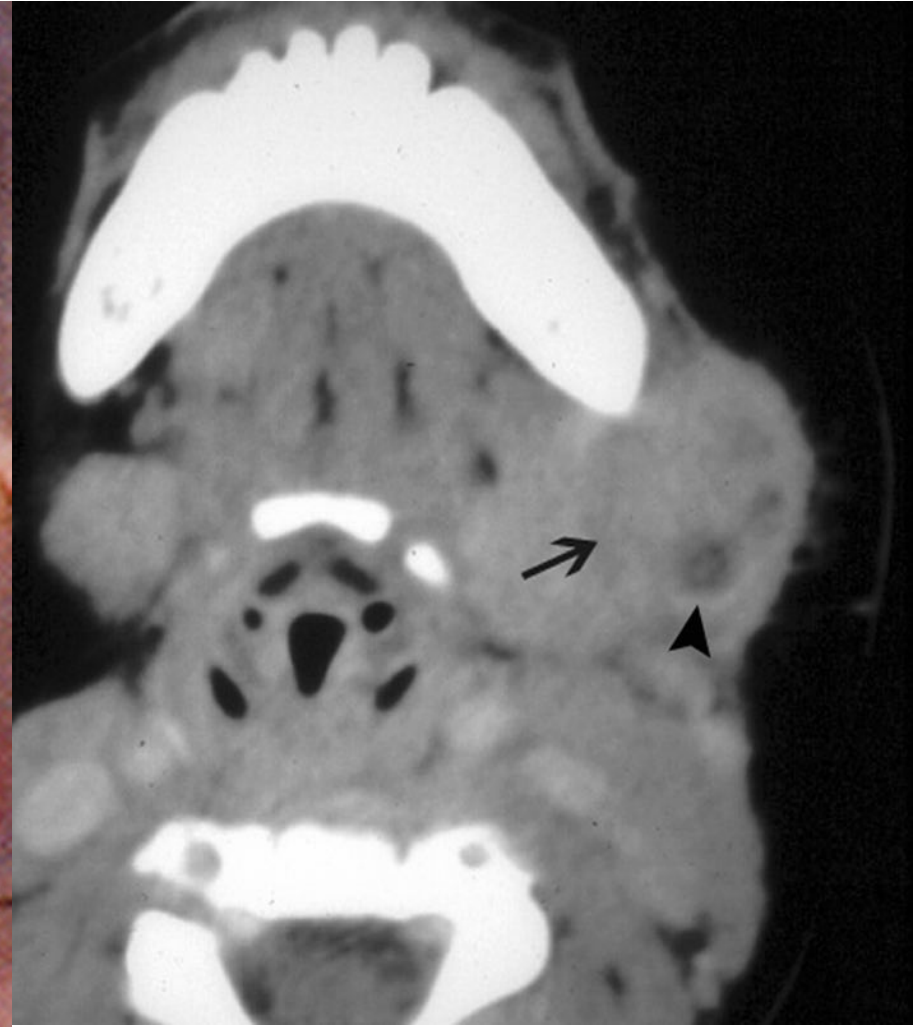
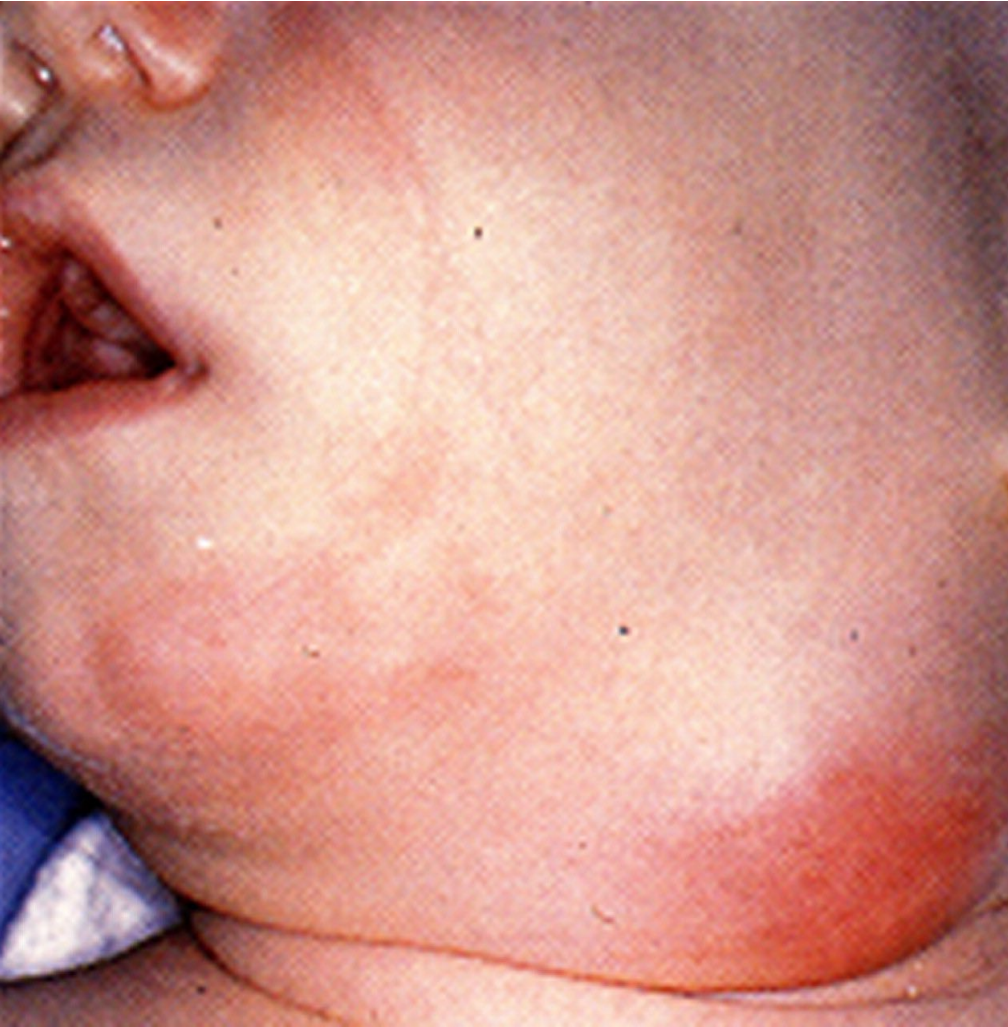Acute epiglottitis

- Children (2-8yrs), adults
- Severe supraglottic infection
- Haemophilus influenza Type B, pneumococcus, β -haemolytic streptococcus
- High fever, inspiratory stridor, dyspnoea, „hot potatoe voice“, drooling, severe pain, imminent asphyxia
- Without treatment lethal in 5-10%!
- Early (!) intubation/intensive care unit
- Antibiotics, steroids, inhalation with adrenaline sol.
- Incidence decreased due to vaccination for haemophilus

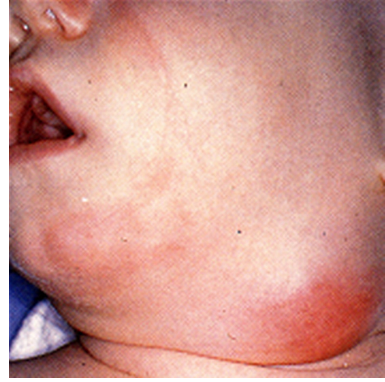



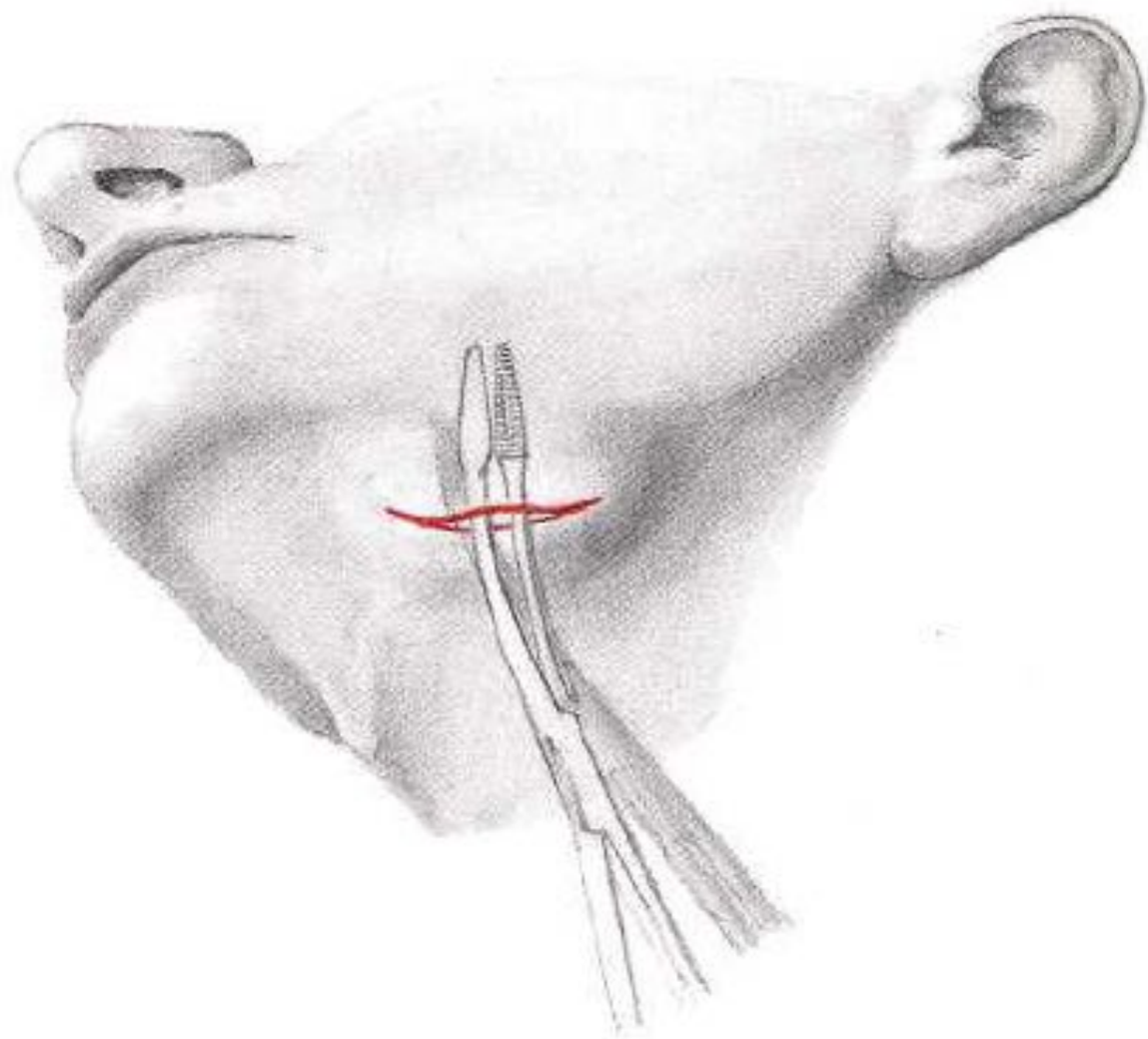
Cervical abscess in a 12 months old child

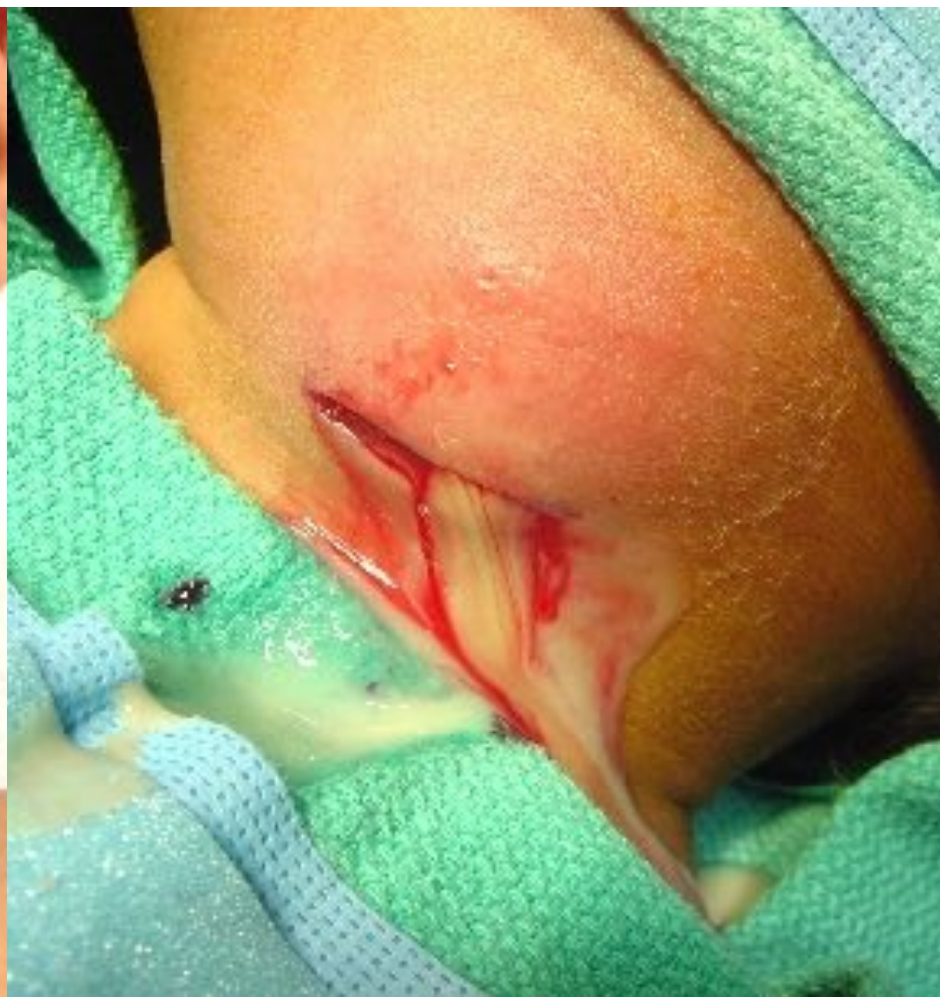
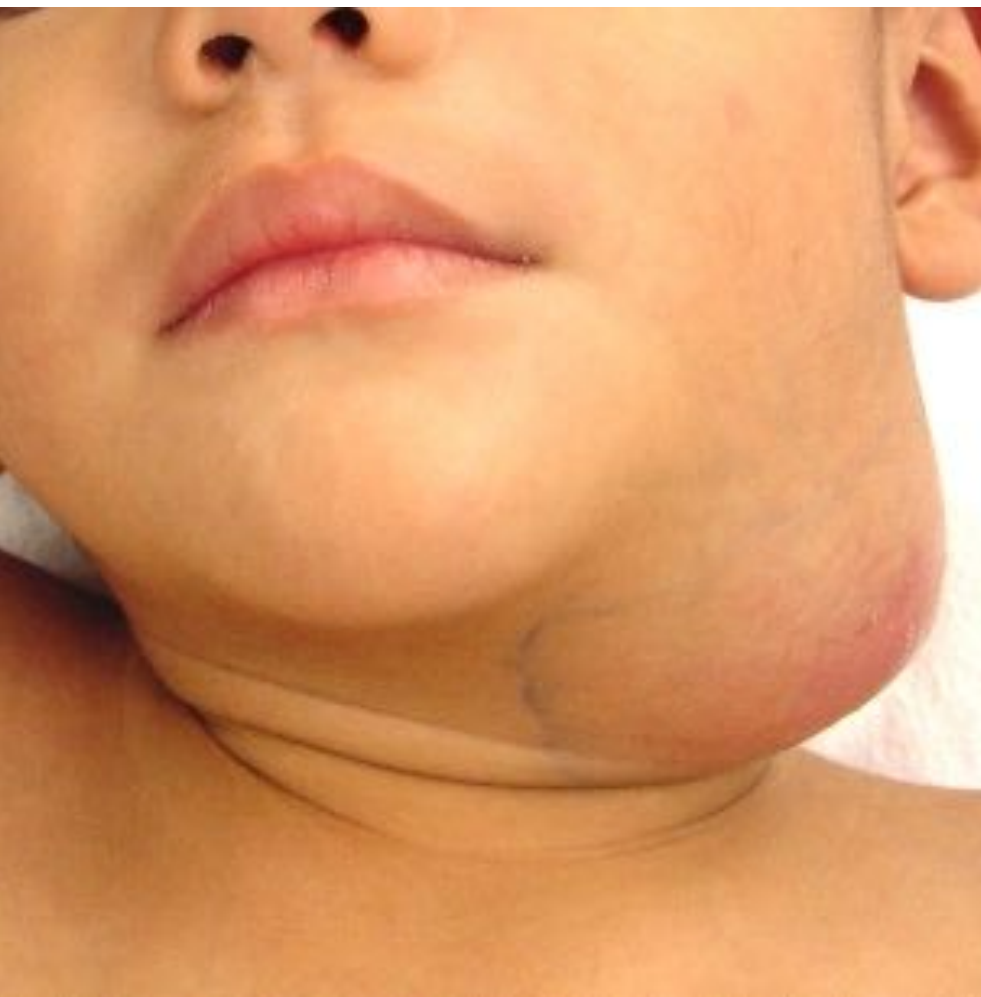
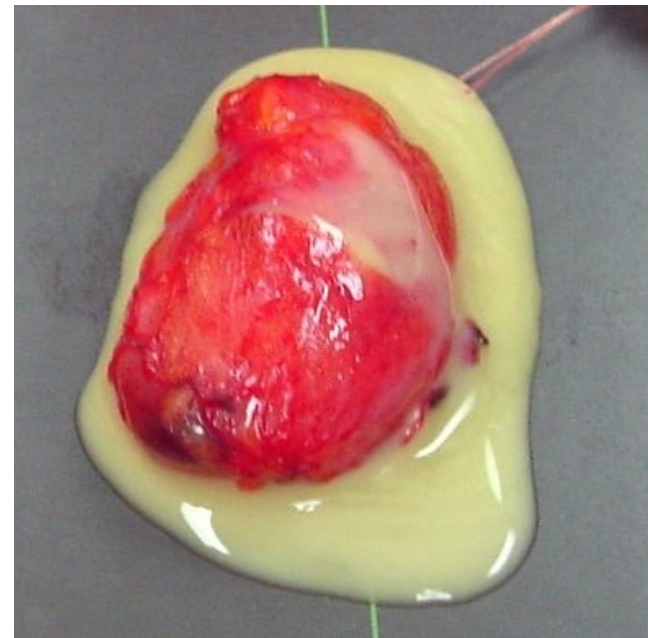
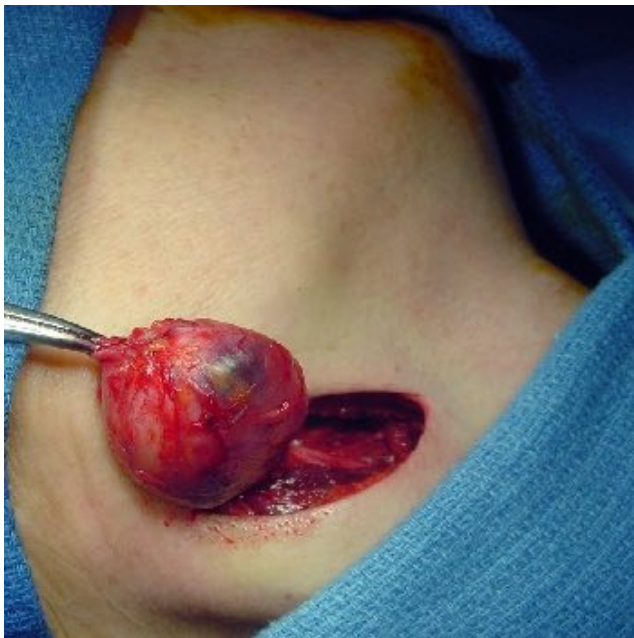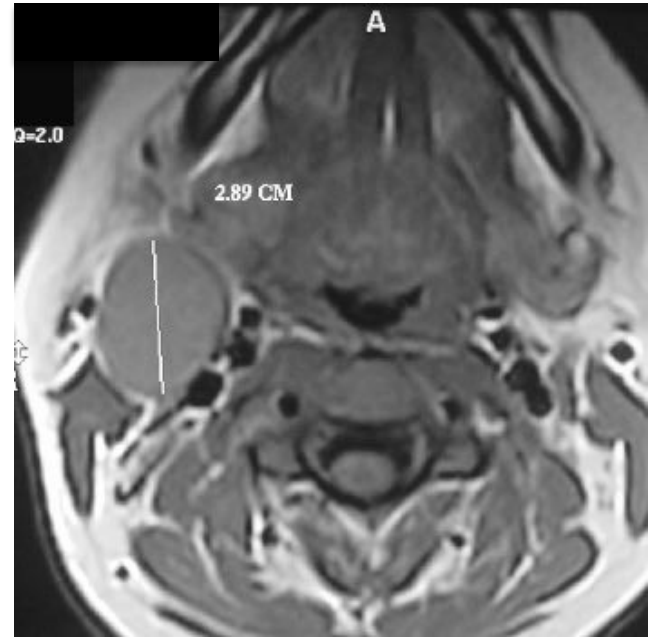
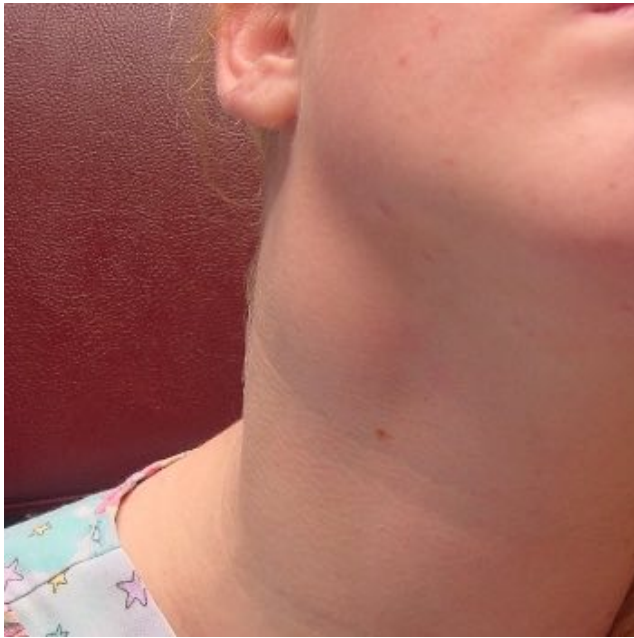Cervical abscess



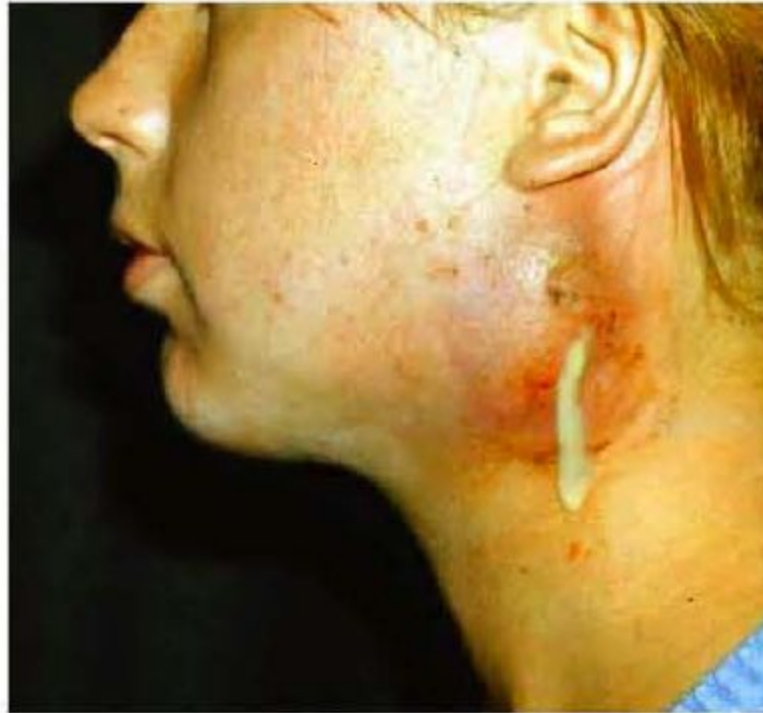- Inside the inter-fascial spaces of the neck
- Caused by: lymphadenitis, lymphogenous (Tonsillitis), per continuitatem (floor of the mouth injury, iatrogenic, teeth or salivary infections), haematogenous (e.g. from skin infection), descending abscess (e.g. from retropharyngeal abscess)
- Cervical swelling, erythema, perforation
- CT/MR/US
- Drainage (peroral/cervical), daily rinsing
- i.v. antibiotic therapy

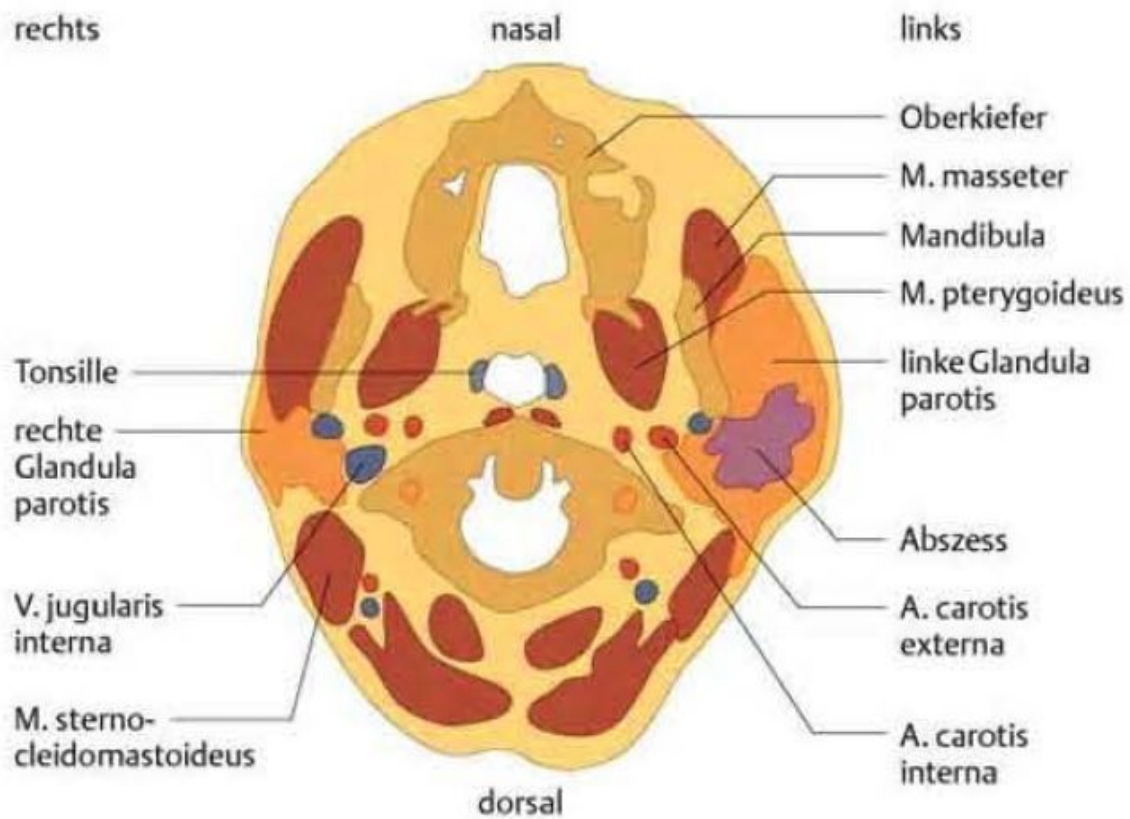
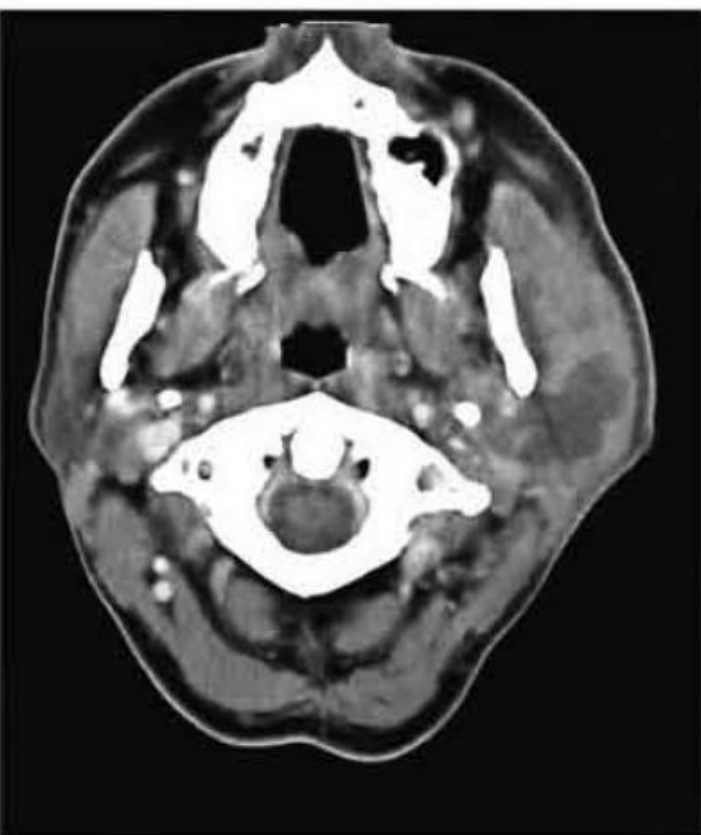


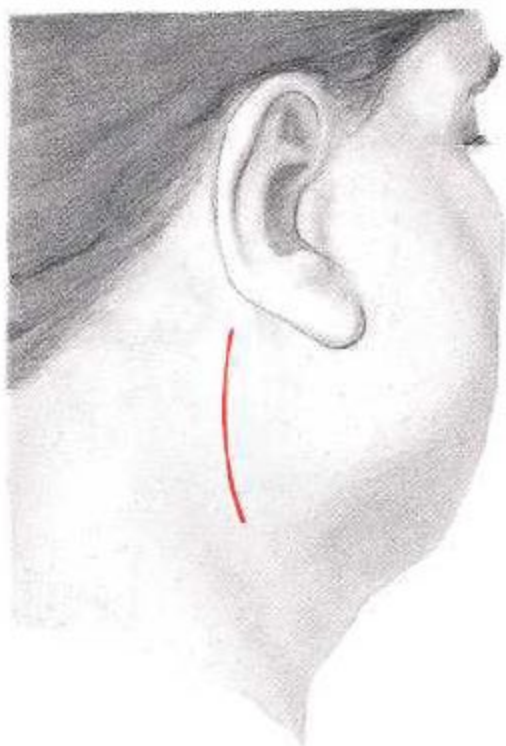



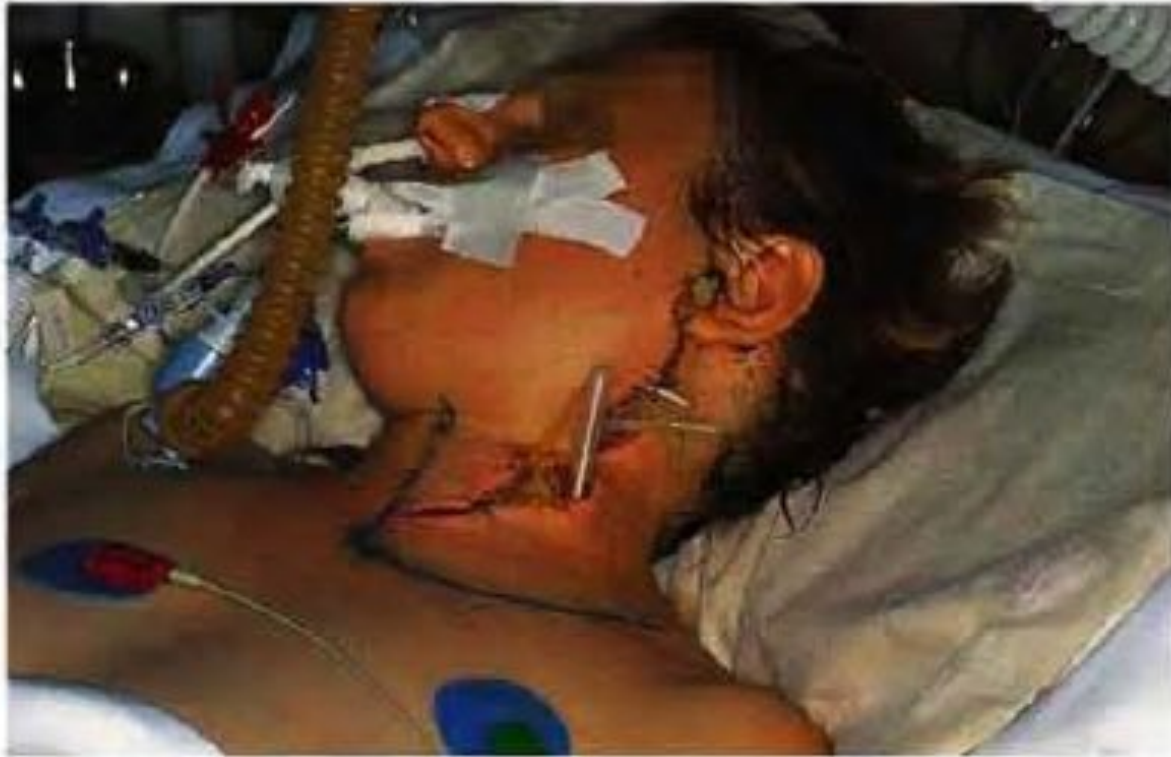Parotisabszess





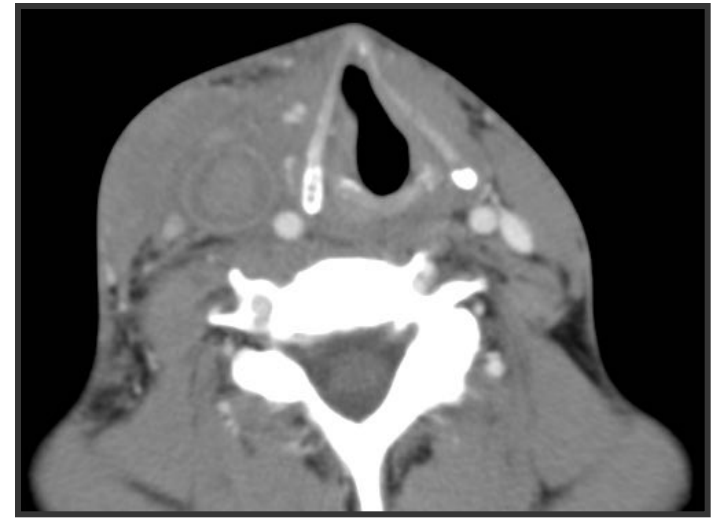


Multilevel cervical abscess



Complications cervical abscess

- septic shock
- asphyxia (airway obstruction)
- vascular involvement with:
 - septic thrombosis of the internal jugular vein (Lemierre)
 - vascular arrosion, pseudoaneurysm of the carotid artery, carotid rupture (with lethal haemorrhage in 40%)
- Involvement of cranial/cervical neural structures:
Horner (Sympaticus), hoarseness (X), tongue paresis (XII)
- Descending abscess => purulent mediastinitis, pericarditis and/or pleuritis



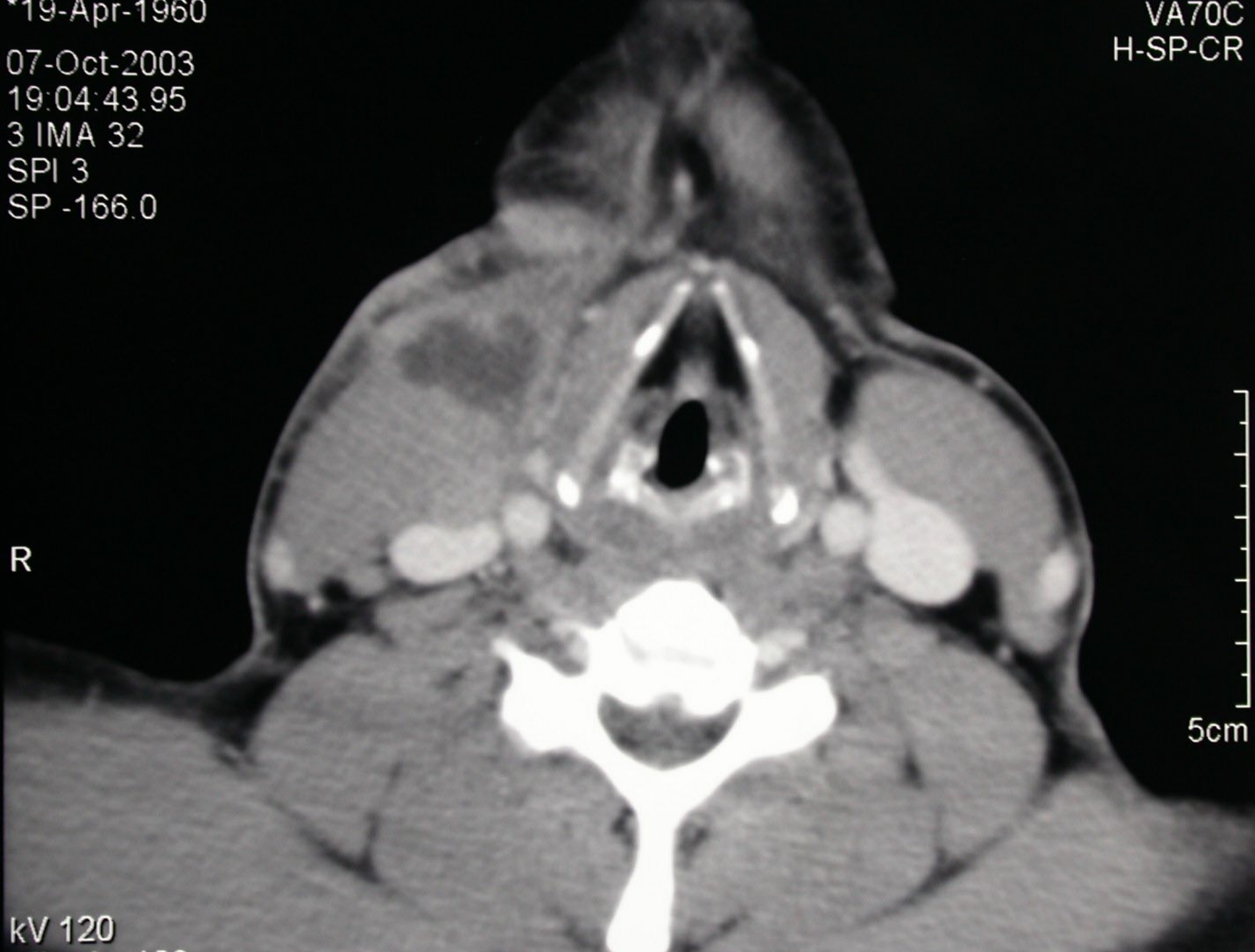
19-Apr-1960
07-Oct-2003
19:04:43.95
3 IMA 32
SPI 3
SP -166.0

VA70C
H-SP-CR

R

5cm

kV 120



Killer-Bakterien

So schlagen sie zu

■ VON BERNHARD WEISSBERG
BERN/LONDON – England ist geschockt: Nirgendwo ist man vor den Killer-Bakterien sicher. Eine junge Frau starb trotz ärztlicher Überwachung nach einer Kaiserschnitt-Ge- burt im Spital einen Tag vor der Entlassung! Sie ist Opfer Nummer zwölf.

«Der Patient stirbt einerseits an den Giften, andererseits an der Lösung des Gewebes», sagt Jürg Munzinger, Leiter der Mikrobiologie am Kantonsspital Luzern, den Engländern gegenüber.

Die Engländer warnen davon, dass die Bak-

terien haben und deshalb so aggressiv sind.

Genauere Zahlen über Opfer gibt es in der Schweiz nicht. Die Krankheit ist nicht meldepflichtig. Aufgrund früherer Zahlen geht man aber von jährlich etwa zwölf Toten aus.

Keine Panik: «Das ist noch sehr wenig», sagt der Leiter der Gesamtbevölkerung, Dr. Desgranges. «Die Gefahr ist aber real».

Todesfallrate nach Ausbruch laut Lehrbuch 47%.

Die Krankheit ist meldepflichtig.

Die Krankheit ist meldepflichtig.

Die Krankheit ist meldepflichtig.

Die Krankheit ist meldepflichtig.

Die Krankheit ist meldepflichtig.

Die Krankheit ist meldepflichtig.

Die Krankheit ist meldepflichtig.

Die Krankheit ist meldepflichtig.

Die Krankheit ist meldepflichtig.

Die Krankheit ist meldepflichtig.

Die Krankheit ist meldepflichtig.

Die Krankheit ist meldepflichtig.

Die Krankheit ist meldepflichtig.

Die Krankheit ist meldepflichtig.

Die Krankheit ist meldepflichtig.

Die Krankheit ist meldepflichtig.

Die Krankheit ist meldepflichtig.

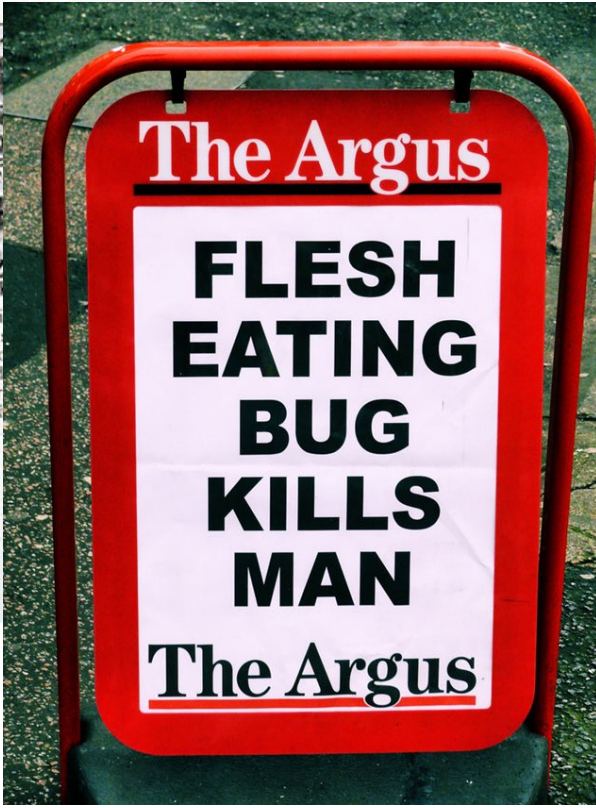Die Krankheit ist meldepflichtig.

Die Krankheit ist meldepflichtig.

Die Krankheit ist meldepflichtig.

**Killer-Bakterien
Tote auch bei uns!**

Entnahme der Streptokokken
Daher der Rat des Spezialisten
Wunden gut desinfizieren. Ist
mehr als eine lokale Entzündung
frühzeitig zum Arzt gehen und
professionelle Wundversorgung
machen lassen, bevor es zu spät ist.

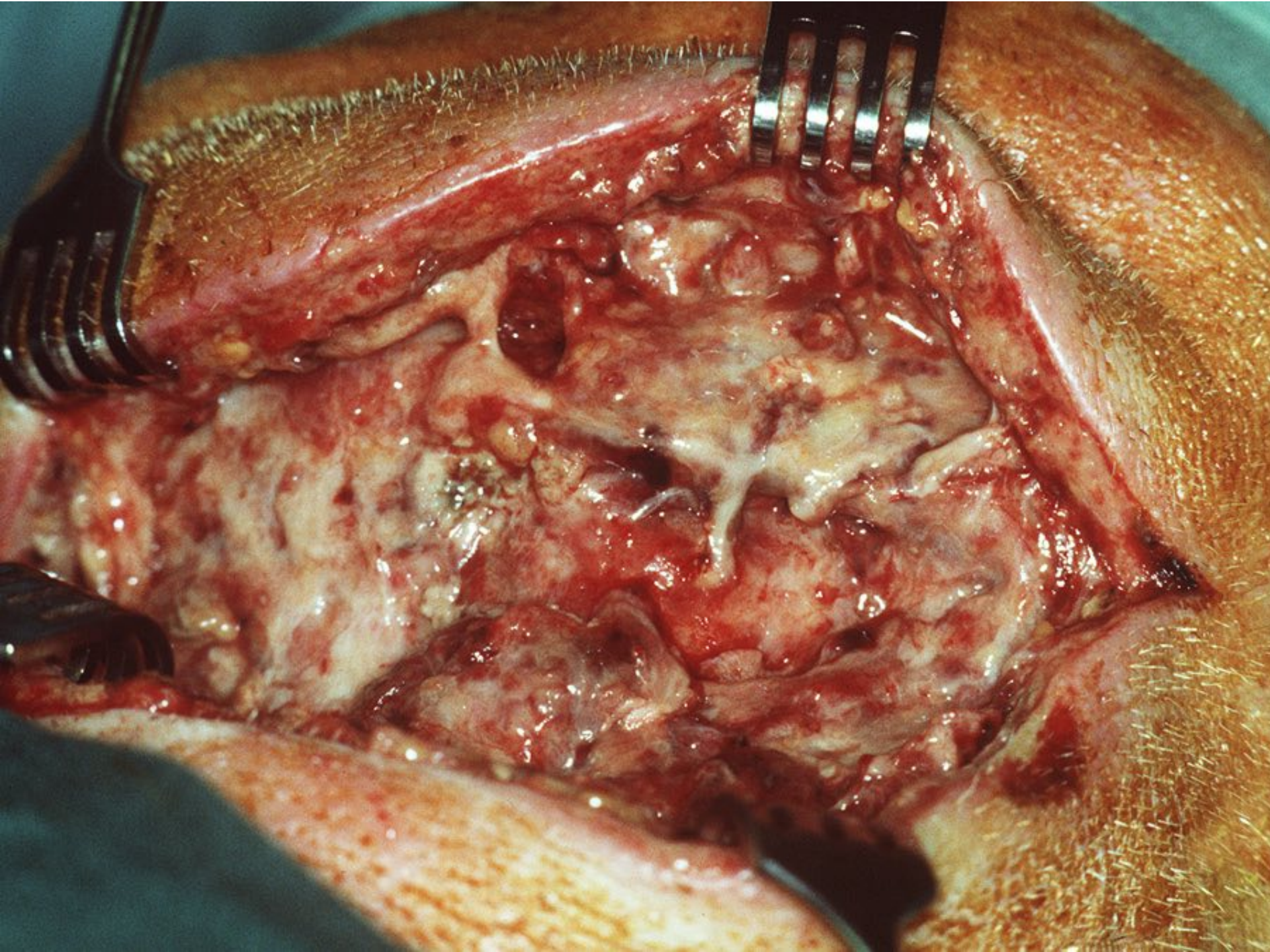


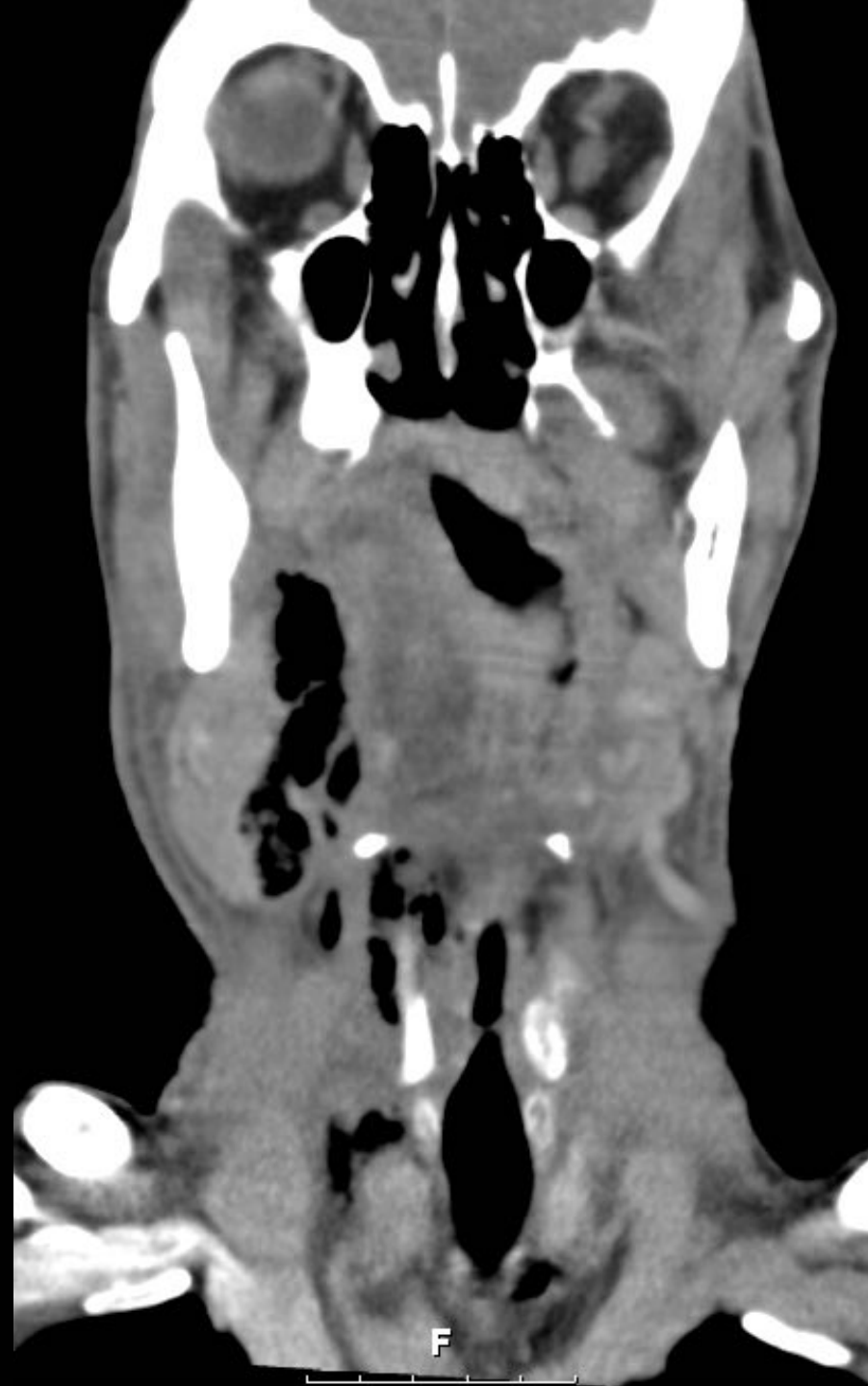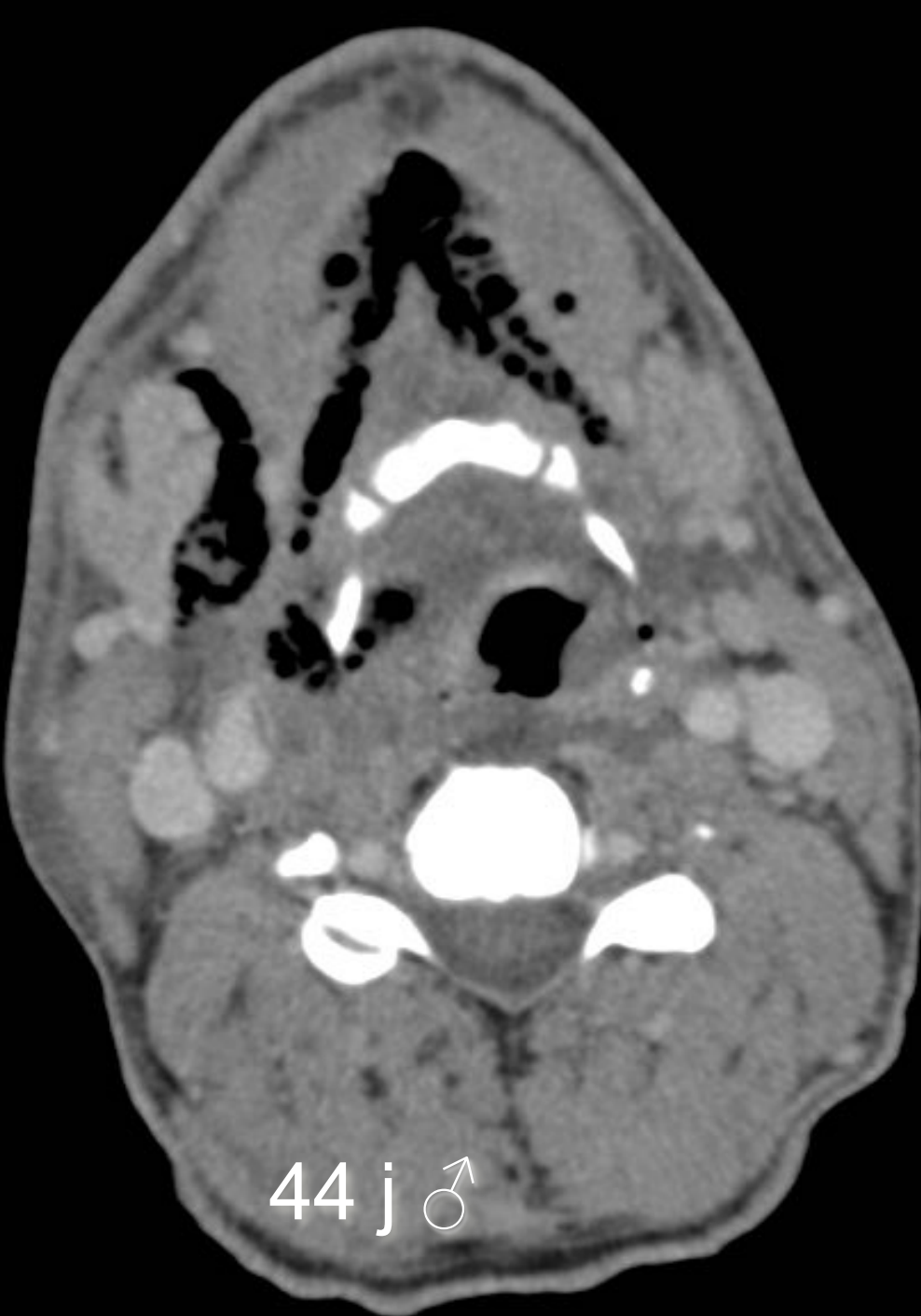
Necrotising fasciitis

- Rapid progressive necrosis of cervical fascias and subcutaneous fat tissue with possible skin and muscle necrosis, accompanied by toxic systemic reaction (1952)
- often mixed flora: often β -haemolytic streptococcus, also staphylococcus, clostridia, gram negative cocci
- Tooth infection, tonsillitis, pharyngitis, (banal) injuries
- diabetics, immune-suppressed, malignoma, but also young otherwise healthy individuals!

Necrotising fasciitis

- Odynophagia, dysphagia, fever, progressive erythematous cervical swelling, septic shock and organ failure within hours!
- CT/MRI
- Emergency cervicotomy with incision and wide opening of all fascial compartments, debridement und drainage. (+/- thoracotomy, often tracheotomy)
- i.v. antibiotic therapy
- Intensive care measures
- High mortality (19-37%)





Head & Neck Surgeon's Infectiology

- Purulent cervical infections may have a rapid and fatal course
- Exceptionally dangerous, when spreading along cervical fascias
- Rapid diagnostics and antibiotic therapy
- Abscesses warrant surgical drainage

Merci!

